



# PEDIATRIC OSTOMY CARE

BEST PRACTICE FOR CLINICIANS



## Table of Contents

Acknowledgements .....	4
Introduction and Overview.....	5
Introduction	
Definitions.....	5
Fecal Diversions	
Stoma Construction	
Rectal Discharge	
Urinary Diversions – Stoma Construction	
Urinary Diversions – Pouching, Cleansing, and Skin Care	
Special Age-Group Considerations: Fecal Diversions.....	9
Premature and Full-Term Infants (Birth to 12 Months)	
Education.	
<i>Developmental considerations.</i>	
<i>Diet.</i>	
<i>Activity.</i>	
<i>Bathing.</i>	
<i>Clothing.</i>	
<i>Pouching tips for premature and full-term infants.</i>	
Toddlers (12 Months to 3 Years) and Preschoolers (3 to 5 Years)	
Premature and Full-Term Infants (Birth to 12 Months)	
Education.	
<i>Developmental considerations.</i>	
<i>Diet.</i>	
<i>Activity.</i>	
<i>Bathing.</i>	
<i>Clothing.</i>	
<i>Pouching tips.</i>	
School-Age (6 to 12 Years)	
Education.	
<i>Developmental considerations.</i>	
<i>Diet.</i>	
<i>Activity.</i>	
<i>Bathing.</i>	
<i>Clothing.</i>	
<i>Pouching tips.</i>	
Adolescents (Approximately age 13 to early 20s)	
Education.	
<i>Developmental considerations.</i>	
<i>Diet.</i>	
<i>Activity.</i>	
<i>Bathing.</i>	
<i>Clothing.</i>	
<i>Pouching tips.</i>	

Pouching Selection and Ostomy Care.....	18
Pouch Selection	
Education.	
Ostomy Care	
Education.	
<i>Emptying the ostomy appliance.</i>	
<i>When to change an ostomy pouch.</i>	
<i>Removing an ostomy appliance.</i>	
<i>Peristomal skin-stoma care during pouch change.</i>	
<i>Cutting the stoma aperture.</i>	
<i>Preparing/leveling the peristomal skin surface prior to pouch application.</i>	
<i>Applying the pouch.</i>	
<i>Care of the mucous fistula.</i>	
Discharge Planning.....	26
Infant	
Education.	
Toddler/Preschooler	
Education.	
School-Age	
Education.	
Adolescent/Teenager	
Education.	
Table 1. Surgical Indications for Fecal Diversions.....	30
Table 2. Surgical Indications for Urinary Diversions.....	37
Table 3. Accessory Ostomy Products.....	40
Table 4. Trouble-Shooting.....	53
Glossary.....	75
Appendix A.	
Resources.....	77
References.....	79
Acknowledgment About Content Validation.....	84

## **Acknowledgements**

*Contributors to the Best Practice – Pediatric Ostomy Care Wound, Ostomy and Continence Nurses Society*

***Kim Bookout, Chair, MSN, RN, CPNP, CWOCN***

***Joanne D'Italia, MSN, CRNP, CWOCN***

***Joann Dudley, MS, RN, CPNP***

***Carol Hafeman, MA, BSN, RN***

***Beth Harrison, MSN, RN, CWOCN***

***Kathy McLane, MSN, RN, CPNP, CWON***

***Valerie Rogers, PhD, RN, CPNP, CWOCN***

***Anita Shelley, MSN, RN, CWOCN, CNS***

## **Introduction and Overview**

The Wound, Ostomy Continence Nurses Society recognizes and supports best practices in ostomy care, involving both fecal and urinary stomas. In pediatric cases, factors such as the growth and development of the child and the need for training and support of parents and caregivers are also involved. This document addresses clinical issues as well as the need for awareness and sensitivity when dealing with an infant or child as patient, and the understandable concerns of parents and caregivers.

### **Introduction**

An ostomy, also called a stoma, is a surgically created opening in the abdomen. There are various types of ostomies. The name of the ostomy is determined by the anatomical location. For example: a colostomy is an opening created in the colon.

Fecal and urinary stomas are constructed from a part of the gastrointestinal tract or urinary tract and divert waste material to the outside of the body. Typically, a stoma is moist, bright pink or red in color, shiny, and feels like the inside lining of the mouth. The stoma may change to pale, gray or white when child is crying but this is temporary and will return to normal color after crying subsides. When a segment of bowel is used to create an ostomy, ideal characteristics would be round in shape; budded above skin level; and sitting on a smooth surface of the abdomen to avoid creases, bony prominences, and suture lines, as well as the umbilicus.

Initially after surgery the stoma will be edematous. This edema gradually decreases within four to six weeks. Because of this change in size it is necessary to resize the pattern weekly and periodically thereafter to account for changes in girth and in abdominal contours, and normal growth and development of the child.

### **Definitions**

#### **Fecal Diversions**

Fecal diversions use a segment of the bowel, which is surgically brought through the abdominal wall.

Three types of fecal diversions are as follows:

1. Jejunostomy, which uses a portion of the jejunum.
2. Ileostomy, which uses a portion of the ileum.
3. Colostomy, which uses a portion of the colon.

## Stoma Construction

The surgeon constructs the stoma in one of three ways: an end ostomy, a double barrel ostomy, or a loop ostomy.

1. **End ostomy** is constructed by taking a segment of bowel, and dividing the bowel in two separate pieces. The portion of the bowel that is coming from the direction of the mouth is called the proximal end. The portion of the bowel that is toward the rectum is called the distal end. The proximal end of the bowel is brought through the abdominal wall and matured. The distal portion of the cut bowel is sewn closed and left inside the peritoneal cavity (or the abdomen). This is called a Hartmann's pouch.
2. **Double barrel ostomy** is fashioned similarly to an end ostomy. The proximal end is constructed the same way as in an end ostomy. The distal end of the double barrel is also brought through the abdominal wall. With a double barrel stoma there are two stomas on the abdomen, which may be adjacent or separated. The proximal stoma is the stoma that drains stool. The distal stoma, also called a mucous fistula, drains mucous.
3. The **loop ostomy** is constructed by bringing a loop of bowel through the abdominal wall. This loop of bowel is cut on the top, halfway through. A rod or ring is placed under the loop of bowel between the skin and the loop. The retention device (a rod or ring created from a Red Robinson catheter) helps support the bowel. The cut edges of the bowel are turned back, like a cuff, and stitched on the skin. The proximal and distal ends are attached at the base of the loop. The retention device is typically removed within the first month postoperatively.

*Note Regarding Stoma Maturation:* Most stomas are matured during their surgical creation, meaning the mucosa is everted and sutured to the abdominal skin, creating a stoma with a "bud" appearance. If the intestinal length is not adequate to mature the stoma, or the vascular supply may be compromised by suturing, the stoma may not be matured. These stomas will appear different than matured stomas. They will, however, spontaneously mature over time and develop the appearance of a surgically matured stoma.

## Rectal Discharge

Despite a properly functioning stoma, patients can occasionally have rectal discharge because:

- The distal bowel may expel stool remaining within it after a stoma is surgically created.
- The distal bowel wall continues to produce mucous which is expelled periodically from the rectum.
- Diversion colitis, an inflammation of the non-functional bowel, may cause dark or foul-smelling rectal discharge. A loop stoma may not totally divert stool, and spillover from the proximal to the distal bowel results in passage of stool from the rectum.

As a result, perianal skin may need to be protected from damage due to contact with stool or rectal discharge (Pediatric Subcommittee of the Wound, Ostomy and Continence Nurses Society, 2010).

## Urinary Diversions – Stoma Construction

Urostomy is a non-specific, general term used to describe urinary diversions. More specifically, urinary diversions include pyelostomy, nephrostomy, ureterostomy, and vesicostomy, as well as ileal and colon conduits.

Urinary diversions are performed for infants and children for a variety of reasons. The most common reason for urinary diversions is congenital abnormalities; however, a urinary diversion may be performed to preserve renal function in children with a poorly functioning urinary system or for malignancy of the bladder.

The stoma for a urinary diversion may be formed from the intestinal tract or may simply involve connecting a section of the urinary system to the skin. Types of urinary stomas include:

1. Conduit (see **Glossary**) – A short length of intestine (ileum or large bowel) is used to form a stoma in the abdomen. The ureters are implanted into the bowel, and this bowel segment is sewed closed inside the abdomen. The distal end of the conduit is brought out onto the abdominal wall and urine drains through this into an ostomy appliance. Mucous from the bowel conduit is often seen in the expressed urine. Conduits are performed in older children when urologic problems are determined to require diversion for the rest of their lives.
2. Vesicostomy – An opening is made through the suprapubic abdominal wall into the bladder and the bladder mucosa is sutured to the abdominal skin to create a small stoma which may have the appearance of a small hole. This stoma may have a catheter for a short time. When well healed, the stoma is usually small, flush, and often in a suprapubic fold. Continuous emptying of the bladder prevents hydronephrosis secondary to vesicoureteral reflux. This stoma is usually managed with diapers, although a school-aged child with a vesicostomy may use an ostomy appliance. Care of the suprapubic skin is important to prevent skin irritation and rashes.
3. Ureterostomy – The ureters are separated from the urinary system and brought out to the skin. This stoma may have a catheter or stent for a short time. Ureterostomies are usually located in the right and left flank area. A ureterostomy manages hydronephrosis caused by upper urinary tract obstruction. Urine flow is typically managed with diapers but ostomy appliances are an option. Skin care must be provided to prevent irritation.
4. Nephrostomy/Pyelostomy – Opening into the renal pelvis for the purpose of diverting urine from the ureters. It is usually performed because of a ureteral obstruction. This is usually accomplished by insertion of a percutaneous catheter through the flank. A nephrostomy is usually a short-term stoma until upper urinary system problems can be corrected. Maintenance of free-flowing tubes and prevention of infection are key care points. Urine is collected in bags attached to the catheter. A nephrostomy may or may not have a tube for drainage.

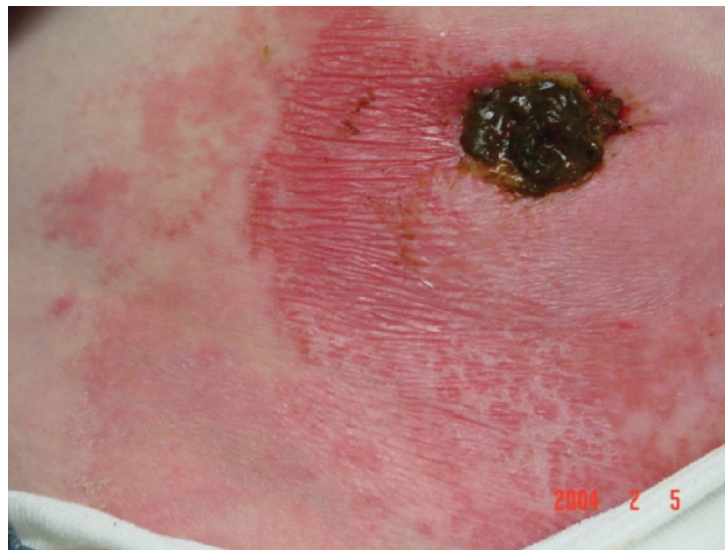
## Urinary Diversions – Pouching, Cleansing, and Skin Care

Urinary diversions that are done in infancy frequently are not pouched. Because the stomas are vesicostomies or ureterostomies, they are flush with the skin and usually difficult to pouch. Unless there is a medical reason to pouch, parents are taught how to protect the skin and contain the urine in the diaper.

It is sometimes helpful to put a smaller disposable diaper or incontinence pad over the stoma, and then use a regular diaper to hold it in place. Sometimes, the diaper will need to be one size larger than the child would usually wear. For older children, suspenders may help keep the diaper up, above the stoma. If the stoma is above the diaper line, especially with pyelostomies, a pouch can be applied, and the bottom end cut off so that the pouch will drain into the diaper.

For many children, simple cleansing of the area with regular diaper changes is enough to prevent skin irritation. However, chronic irritation and rashes become a problem for some children. Generally, application of a petrolatum ointment (Vaseline, A&D ointment) on intact skin is sufficient to prevent skin irritation due to urine. However, yeast on the skin surrounding the stoma is a common problem. Parents need to know what yeast looks like and have treatment option (antifungal ointment, cream, or powder) available to them at all times.

**Photo of Yeast**



Urinary stomas that are pouched require pouches made for urine. These pouches offer two significant advantages over ostomy pouches made for fecal stomas. First, urinary pouches have a spout for emptying—a clear advantage with liquid drainage. This also allows the pouch to be connected to dependent drainage while the child sleeps. Using dependent drainage will definitely improve wear time of the pouch. Second, urinary pouches have a built-in anti-reflux valve. This prevents urine from pooling around the stoma once it drains to the bottom of the pouch, which promotes longer wear time. It is helpful to make the stomal opening a little larger than one would for a fecal diversion. This is especially true if the stoma is flush (see **“Special Age- Group Considerations: Fecal Diversions”** and **“Pouch Selection and Ostomy Care”** sections).



Vesicostomies have a tendency to develop stenosis, and parents may need to insert a catheter or a metal dilator to dilate the stoma once or twice daily. If there is concern (especially as the child grows) that the bladder is not remaining empty, the parents may need to use a catheter and drain the bladder. This is a clean technique, washing the catheter after each use and reusing it several times, depending on the protocol of the institution. Lubricating jelly is used to help insert the catheter through the opening.

Note: Urinary pouches may also be used for high output fecal ostomies (jejunostomies) or other ostomies with excessive output (e.g., leaking gastrostomy).

### **Special Age-Group Considerations: Fecal Diversions**

**Statement:** At each stage of development – from infancy, preschool and school-age to adolescence and young adulthood – there are special considerations in ostomy care. Best practices need to be defined, developed, and followed in order to provide safe, effective, and age-appropriate ostomy care.

#### **Premature and Full-Term Infants (Birth to 12 Months)**

**Education.** Premature and full-term infants (birth to 12 months) have specific ostomy care needs due to developmental considerations. Caregivers and parents need special training in order to provide safe and appropriate care, minimizing risks such as damage to immature skin and organ systems. These care considerations should not be viewed as an obstacle to parent-child bonding. Rather, supporting that essential bond should be an objective of ostomy care education for families.

**Developmental considerations.** Infants are too young to realize they have an ostomy, or that their stoma makes them different from other infants. Parents and family, however, are very aware of the stoma and may grieve over the loss of their “perfect” child. Furthermore, physical demands on the sick infant may prevent parents from bonding with their baby. Parents/caregivers should be encouraged to visit often and participate in the infant’s routine care, including ostomy care. Caring for and cuddling their infant while in the hospital encourages parent-infant bonding, and supports the infant’s development of a sense of trust by meeting the child’s physical and emotional needs. Allowing and encouraging families to perform routine care while in the hospital also helps prepare them for caring for their infant and the stoma after discharge.

Newborns, particularly premature infants, are physically very different than older children or adults. Many developmental considerations of children in this age group are related to their physical immaturity. Caregivers must become knowledgeable about these differences to avoid harming an infant with inappropriate ostomy care practices. Physical developmental considerations for premature infants and term neonates are discussed below. Ostomy care practices for older infants are generally similar to those of toddlers.

Full-term infants are born with an mature epidermal barrier similar to that of an adult. Premature infants have an epidermal barrier that is immature, or in the low-birth weight infant, virtually non-existent. This leads to transepidermal water losses (TEWL), as well as greater absorption of topical agents through the skin. Risk of chemical and friction injury is also greatly increased.

The epidermis and dermis (the top two layers of skin) are strongly bonded in adults, minimizing stripping or removal of the epidermis with adhesive removal. Infants, particularly premature infants, have a weak bond. This contributes to epidermal stripping when adhesives are removed from the skin, as well as friction injury and blistering of the skin.

The ratio of surface area to body weight in a newborn is 3 times that of an adult and even greater in the premature infant. The result may be TEWL and elevated systemic levels of chemicals absorbed through the skin.

Infants experience greater toxicity to chemicals absorbed through the skin compared to adults because their immature hepatic, renal, and central nervous systems cannot metabolize and excrete them efficiently.

The acid mantle (slightly acidic pH) of the skin provides a barrier to microorganisms. It develops within four days of birth in the term infant, but more slowly in the premature infant. Application of topical substances may disrupt the acid mantle, resulting in vulnerability to microbial invasion through the skin.

Infants are at risk of nutritional deficiencies as a result of a shortened GI tract and decreased absorptive area after bowel resection and intestinal diversion (fecal stoma). Deficiencies may also result because of the high energy expended during illness and rapid growth and, in premature infants, because of the loss of nutrients stored in late gestation.

**Diet.** Generally, infants with a stoma can eat normal infant foods and formula without restrictions imposed by the presence of a stoma. Infants with a disease resulting in malabsorption, or who have undergone bowel resection with potential for short bowel syndrome, may be on special diets or formulas. The pediatric surgeon, pediatric gastroenterologist, and nutritionist will follow these infants closely and make dietary recommendations.

**Activity.** Infants with stomas have very few restrictions on their activities as a result of having a stoma, and can be treated like any infant of comparable age and health. Without fear of harming the stoma, they can safely:

- Be hugged and held closely chest-to-chest. This is essential for normal infant development.
- Be buckled into an infant care seat or stroller.
- Be placed on their abdomen (“tummy time”) to play. Prior to placing the infant in the prone position, the pouch should be emptied to prevent disruption of the seal due to pressure on the pouch. As with any infant, caregivers should follow “Back to Sleep” guidelines (The American Academy of Pediatrics recommendation that infants sleep in the supine, rather than prone, position).

**Bathing.** In the neonatal period, routine soap bathing is not recommended. Spot bathing, with or without soap, to remove debris may be adequate. Hospital policy on neonatal skin care should be followed during hospitalization.

Infants with a stoma can be sponge-bathed (while the umbilical stump remains), or immersed in water (tub-bathed) after the cord falls off and sutures are removed, if their medical condition allows. Tub bathing can be done either with or without a pouch in place, with these considerations:

- If tub bathing without a pouch, the bath can be timed to coincide with planned or unplanned pouch changes and performed according to normal bathing routine. Cleanse the peristomal skin gently using water and a soft cloth;
- Soap residue should be rinsed from the skin with clean water prior to pouch application;
- Tub-bathing with a pouch in place generally will not disrupt pouch adhesion.

After bathing, the pouch should be thoroughly dried on all sides to prevent moisture from being trapped against the skin. Drying the pouch with a hairdryer may result in burn injuries and is not recommended.

Infants with urinary stomas may or may not be allowed to submerge their stoma in water, at the discretion of the surgeon.

**Clothing.** Older infants will frequently pull off their pouches as they explore their environment. One- piece sleepers and T-shirts that snap at the crotch help deter exploring hands. However, any normal infant clothing is acceptable.

**Pouching tips for premature and full-term infants.** Ostomy care for the premature and full-term infant cannot be carried out using the same guidelines as those used on older children and adults. Specialized care is required to protect infants from iatrogenic injury (see “**Special Age-Group Considerations: Fecal Diversion, Premature and Full-Term Infants (Birth to 12 Months), Education., Developmental considerations.**” section).

The pouch wafer should be large enough to accommodate all stomas to be pouched within the same appliance, with adequate wafer remaining to secure the pouch to the skin. Infants with multiple stomas may require an adult-sized wafer or multiple neonatal/pediatric wafers. An infant with a prolapsed stoma may require an adult-sized one-piece pouch to avoid trauma to the stoma.

Infants with liquid stool may benefit from use of a urostomy pouch. Stool can be drawn out of the tap/ drainage tube with a syringe if output is being measured. High output fecal stomas can be pouched with a urostomy pouch, with the pouch connected to a urine collection container.

Some infant pouches come with soft cut to fit wafers, separate from the pouch. These pouches may be mistakenly used without the wafer. With this style pouch, the two components, wafer and pouch, must always be used together. Use of adhesive remover/solvent to remove a pouch on a premature infant is discouraged due to the risk of toxicity from absorbed chemicals in the adhesive remover. Its use can be considered in situations in which an aggressive adhesive would strip the epidermis with removal. Adhesive remover should always be cleansed from the skin promptly with soap and water.

Although a warmed wafer more readily conforms to the skin contours, do not warm a barrier under a radiant heater. Application of an overheated wafer will quickly burn fragile skin. Holding appliance between two hands or between an arm and flank should be adequate to soften the wafer to apply.

Avoid laying an immobile infant on the pouch closure, particularly a hard plastic clamp-style closure. This could result in traumatic skin injury or pressure ulceration.

A pouch can be worn inside or outside a diaper. When worn inside, moisture from the wet diaper may erode the wafer. Picture-framing the wafer with waterproof tape can improve wear-time. If worn outside, a loose-hanging pouch may be pulled off or become entangled on objects as an infant navigates the environment.

Infants swallow large amounts of air with sucking and crying, and fill their pouches with air. Gas filters added to the pouch can decrease frequency of pouch emptying and increase wear time, but once they are wet, are no longer effective.

A two-piece pouching system allows rapid “emptying” of the pouch in an older, active infant. The soiled pouch can be snapped off and exchanged for a clean pouch, and then rinsed and reused when the pouch next needs emptying.

An infant ostomy appliance should be able to remain intact for at least 24 hours, or up to four days, with an average wear-time of two to three days. Wear-time decreases in premature infants, and acceptable wear-time may initially be 12 to 24 hours. Routine pouch changes, scheduled before expected wafer failure, may help prevent leakage and skin damage.

Ill infants with stomas often have central lines in place. Because of the infant’s small size, central lines come in close proximity to the pouch. Care should be taken to prevent central line contamination with stool (Pediatric Subcommittee of the Wound, Ostomy and Continence Nurses Society, 2010).

Following stoma closure, perianal skin breakdown is common. Measures should begin immediately following stoma takedown or closure to protect perineal skin (Pediatric Subcommittee of the Wound, Ostomy and Continence Nurses Society, 2010).

### **Toddlers (12 Months to 3 Years) and Preschoolers (3 to 5 Years)**

**Education.** As a child grows, his/her ostomy care should reflect development and advancements in physical and cognitive abilities.

**Toddler (12 months to 3 years).** Children of this age are exploring the physical environment and maintaining self-esteem. Egocentric individuals with magical concrete thinking processes, toddlers are often mistaken about causality of events and must be reassured that their behavior was not the cause of their medical condition. Toilet training should be pursued for urine or stool that is not diverted, if anatomically feasible. The older toddler should be encouraged to participate in stoma care to foster autonomy. While the caregiver will need to perform most of the actual stoma care, a toddler can assist by holding the pouch or tail clip and in gathering supplies. Dolls or stuffed animals are useful teaching tools and allow the child to “play out” their situation and to practice skills.

**Preschool (3 to 5 years).** At this stage, children are beginning to initiate rather than imitate activities, as well as to develop a conscience and a sexual identity. As they master tasks they also begin to fantasize and have strong concerns about their body’s physical integrity with the skin protecting inner body parts. It is important to correct misconceptions and be aware that they have big imaginations, as well as an intense fear of pain, mutilation, and the supernatural. They are anxious to learn, but have a narrow focus. They believe in

absolutes, making it hard to change their minds. Simple concrete instructions and explanations are easiest for the preschool child to understand.

Early self-care promotes confidence and independence. Simple pouching systems that can be mastered by the child are favored. Preschool children have an attention span that increases during this time from 10 to 30 minutes, and manual dexterity that improves as well. Teaching sessions should be short and with frequent practice opportunities for best effect. Dolls and stuffed animals are useful. There are companies that provide dolls with a stoma to assist in teaching techniques of pouch changes.

**Diet.** There are generally no restrictions unless the child has an ileostomy or short bowel syndrome. With an ileostomy, it may be helpful to cut food into small bites. Food may come out whole in the pouch because young children don't chew food well. Encourage increased fluids. If child has short bowel syndrome, nutrition services should be a part of the care team.

**Activity.** Do not limit activity. To improve pouch wear, binders, belts, or clothing modifications may be helpful. Binders can provide extra support to the pouch for the very active child (see Table 3).

**Bathing.** Children can bathe with or without the pouch. Parents who worry about water entering the stoma during bathing should be told that it is not harmful to the stoma if a small amount of water does enter. Parents should be assured that it is safe to bathe without the pouch. However, stooling can occur during bathing.

If a schedule is established for every-other day pouch change, caregivers may want to do a full bath on the day of the pouch change. A modified bath with less water in the tub is suggested for days the pouch will not be changed; keeping the water level below the pouch. Bubble baths should not be used. Limit the amount of soap in the water and avoid soaps with lotion, as pouch adherence will be compromised.

**Clothing.** One-piece outfits are helpful to keep children from pulling off pouches and to keep the pouch from being caught on objects during activity.

### **Pouching tips.**

- Keep pouching simple. Use as few products as possible. It sometimes helps to tape barrier edges if the toddler is very active and/or the barrier edge lifts up prematurely.
- Typical wear time may be two to three days, but sometimes pouches need to be changed daily. It is recommended that a routine pouch change schedule be established as this helps parents fit stoma care into busy family life and decreases changes at inconvenient times.
- Reassess stoma for size change during the first six weeks postoperatively. Afterwards, reassess stoma size periodically because the stoma will grow as the child grows.
- Short pouches (6- to 10-inches) are usually appropriate for the size and activity level of children in this age group. However, some children will need a larger pouch to accommodate larger volumes of stool and gas. If a larger pouch is used, positioning the pouch to the side instead of toward the feet may help to accommodate the larger pouch, as it can be tucked into clothing and is less likely to get caught on objects while the child plays.

- If gas output is excessive, gas filters are helpful but are not commercially incorporated into most pediatric-sized pouches. They can be added to pouches, if needed (see Table 3). The filter will need to be covered per manufacturer's instructions when bathing or in water to maintain its efficacy.
- Two-piece pouching systems provide the flexibility to use different sized pouches for day and night- time. This is especially helpful when gas and/or larger volume effluent is a problem at night. Parents of active toddlers may find it easier to remove the pouch to empty and cleanse it, while placing a second pouch onto the flange.
- If stool is liquid, a urostomy pouch may be the appropriate choice and allows for use of a urine collection container during sleep (see Table 3).
- Convexity is needed when the stoma is flush with the skin, retracted, or there are creases and/or healed incisions that cause irregularities on the peristomal skin. Convexity can be created by adding pieces of barrier supplement/strips to the wafer before it is applied to the toddler (see Table 3). A limited number of pediatric pouches are manufactured with convexity.
- Pouch closures will vary for this age group. Some parents find flexible wire closures work well and are soft. Other parents prefer the non-disposable plastic clamp-style pouch closures, as they may provide more security and are easier to manipulate. Some pouches now have interlocking, non-adhesive closures which have been well received by parents.
- Binders may be more helpful than belts to secure the pouch with this age group, especially if the child has two stomas and pouch adherence is an issue. Binders can be sewn by family members or can be custom-ordered through some companies (see Table 3).

### **School-Age (6 to 12 years)**

**Education.** Increases in physical and cognitive abilities require changes in ostomy care for older children, age 6 to 12 years, to foster independence and support maturity.

**Developmental considerations.** Children at this age are mastering new skills. Each experience, even if frightening and painful, is a challenge to be overcome, and children coached in how to perform tasks adapt most effectively. Since they are accustomed to dealing with adults in school, they are often more easily taught than adult patients. In fact, they are often more ready to learn than their parents.

Manual dexterity, emotional maturity, and cognitive function vary tremendously from the beginning of this period to the threshold of adolescence. These factors are also influenced by family culture and climate, the child's innate abilities and life experiences, and the impact of the medical condition and treatment on both child and family.

Best practices encourage teaching the child and parent/caregiver together. Give the child steps to perform as his/her "job" based on skill level and confidence. As the child gains competence and confidence, he/ she can be given more responsibility. Steps that can be delegated include gathering needed supplies, keeping track of the pouch closure, and removing the soiled appliance.

Giving school-age children control of removing adhesives can take longer, but can also decrease the amount of pain they experience. Removing the adhesives themselves can help them to master the pain by controlling the speed at which they experience it.



Older school-aged children with sufficient dexterity and maturity can be almost totally independent in self-care, whereas the younger school-aged child may function more as an “able assistant.” It may be necessary to coach parents in delegating and supervising rather than doing for their child if the ostomy is to be longer term. This will give the child the needed freedom to participate in overnights, attend camp, and be more self-confident at school and away from home.

Repetition will promote learning the steps of care. Because this is a new skill for parents and child, staff should minimize variation in their teaching until the skill is mastered.

### **Diet.**

- Colostomy: No restrictions.
- Ileostomy: The child should chew food well, and eat slowly. Review foods that can cause obstruction. Foods that are prone to cause obstruction should be tried one at a time. Drinking eight to 10 glasses of fluids daily is recommended for the child. It may be necessary for the child to drink extra fluids while eating foods high in fiber, as well as increasing fluids during illness, after exercise, and during warm weather.

### **Activity.**

- All activities are generally allowed, after obtaining a release from the surgeon.
- Protective gear to protect the stoma may be worn for contact sports.
- Active children may require more frequent pouch changes. Belts or binders can be helpful to support pouch adherence (see Table 3).
- Discuss gym and showering at school with the child and parent/caregiver, as well as having ostomy supplies in a location such as the office or clinic at school for emergencies.

### **Bathing.**

- With or without pouch.
- Discuss showering and turning stoma away from the spray of water.

**Clothing.** School-age children often prefer baggy clothes, especially initially following ostomy surgery. Swimsuits with patterns, a skirt front, or gathered appearance help conceal the ostomy pouch.

### **Pouching tips.**

- Smaller abdomens don’t necessarily mean smaller output. Infant-sized pouches often seem a better size match, but may not have aggressive enough adhesive or large enough pouch capacity for effluent volume. Most ostomy manufacturers have smaller sized adult pouches that may fit well for school-age children.
- Hipbone and rib cage are often closer to the stoma than is ideal in unplanned (un-site marked) situations and may preclude the use of a two-piece pouch. Ideally, stoma site marking is a priority if possible in the planned ostomy surgery for the school-age child or adolescent. One-piece pouches are often more suitable since the activity level of these children may result in shorter wear times (one to three days for a urostomy, three to four

days for an ileostomy and colostomy). Frequent flexing of the flange can cause premature separation with a two-piece system.

- If a two-piece pouch is suitable and desired, it offers several advantages, such as the ability to use a closed-end pouch. This is especially useful for wheelchair-bound children, to prevent a pouch closure from putting pressure on their skin. It is also helpful for school-age children who cannot empty their own pouches independently and hygienically, but can manage snapping pouches off and on neatly, and for whom the pouch closure is often uncomfortable due to their shorter torso. Drainable pouches in different sizes can be used, if necessary, for day and night.
- Another useful item for school-age children is an add-on gas filter/vent (see Table 3) to help eliminate gas and prolong periods between emptying the pouch. The filter will need to be covered per manufacturer's instructions when bathing or in water to maintain its efficacy. This is helpful even with two-piece systems, as "burping" the pouch (unlocking the two pieces at the flange slightly to allow air to escape) can be messy.
- Pouches are usually positioned toward the feet but may also be tilted slightly to the midline or to the side.
- Schedule pouch changes before expected barrier failure. Wear time is generally two to four days. Best time to change the pouch is in the morning when the bowel is less active.
- Belts (**see Table 3**) may be helpful to secure the pouch, especially for active periods. Cloth pouch covers are also helpful, and can be sewn by family members or fashioned from terry-cloth washcloths, etc.
- Waterproof tape picture-framed around the wafer is helpful for water activities.
- Reevaluate children as they grow for possible change in pouching system.

## **Adolescents (Approximately age 13 to early 20s)**

**Education.** At this stage of development, adolescents are often capable of becoming their primary caregivers, and should be treated and trained as such. Sensitivity and understanding are required to deal with emotional issues related to adolescence (from rebellion to identity) which can impact health and ostomy care.

**Developmental considerations.** Adolescents are developing their identity and are subject to role confusion. Ostomy surgery can complicate this process and both adolescent and parent/caregiver may become excessively focused on the ostomy rather than the "bigger picture" without expert guidance. Adolescents need time to discuss the impact of their new stoma on all their daily activities: hygiene, diet, sports and recreation, social situation, and, if they indicate concern or interest, their sexuality. Time should be allotted to discuss issues of concern with both the adolescent and parents together, as well as with the adolescent in private.

Teach the adolescent as the primary caregiver, but include adequate instruction for parents to provide back-up support and oversight. Adolescents need privacy, but are dependent on parents who usually provide transportation, food, clothing, and shelter.

Adolescents do not plan ahead well and tend to minimize problems until they have escalated. When they act out in anger, fear, or rebellion, it can impact their health. Adolescents have been known to "run away" (i.e., take off for a day or two) without ostomy supplies, or to "forget" to order supplies in advance, and notify an adult only when their supplies are totally depleted.



Although not magical thinkers like younger children, adolescents do not always fully comprehend their illness, nor do they anticipate the consequences of their actions, including developing peristomal ulcerations from inadequate cleansing or going too long between pouch changes.

### **Diet.**

- Ileostomy: Encourage eating slowly and chewing well. Increasing fluids during and after exercise, in warm weather, and when ill. Review foods that cause obstruction. New foods should be tried one at a time, and eating should be in moderation.
- Colostomy and ileostomy: Discuss foods that cause increased gas and odor so adolescents can plan their diet accordingly when eating out with friends.

**Activity.** Support the adolescent's interest in sports. However, the type of pouch seal used may be an issue depending on activity, as well as the type of pouch worn for the sport. Adolescents with an ostomy need to feel secure. Belts (see Table 3) may be helpful. Contact sports should be cleared through the surgeon, but are usually acceptable.

### **Bathing.**

- May be done with or without pouch.
- Discuss showering techniques.

**Clothing.** Adolescents are usually concerned with how the ostomy will be concealed under their clothing. Clothing should cover the abdomen and not be too tight as to constrict the pouch. Longer, looser fitting shirts may be helpful.

### **Pouching tips.**

- Choice and control are as important to adolescents as they are to adults, so involve the adolescent in pouch selection. Health care providers can recommend best options and explanations as to why they may be best, but sometimes the adolescent will prefer to try other options, and will appreciate choices.
- Adolescents with temporary stomas often start with a simple one-piece pouch and advance to a two-piece pouch when wear time or other issues arise. Others prefer a two-piece pouch from the start.
- Smaller, shorter torsos make the 12-inch pouches too long, and also encourage less frequent emptying that can compromise the seal. The shorter 9- or 10-inch pouches work well for many, although some adolescents with an ileostomy find they need a larger pouch at night. Some girls use a two-piece pouch, with a 6-inch infant pouch during the day and a larger pouch at night.
- Some adolescents report that the flanges on a two-piece pouch come apart during sports and activity, despite use of a belt. Therefore, they prefer the one-piece style for more security. Other adolescents add a belt or a hernia binder (see Table 3) with an anti-prolapse over-flap for extra security.
- Older boys have more abdominal hair and might require a depilatory or regular shaving to improve pouch adhesion. Always patch test depilatory on the skin for 24 hours prior to using around the stoma. This can detect the potential for allergic reactions that will interfere with pouch adherence and cause skin breakdown.

- Retracted stomas usually require convexity. Flush stomas may require convexity or the addition of a barrier ring (Pediatric Subcommittee of the Wound, Ostomy and Continence Nurses Society, 2010).
- Thinner adolescent girls often have concave abdomens. Pouching using convexity and a belt can be challenging, as the belt may pull upward over the hipbone.
- Keep the number of products to a minimum when teaching an adolescent stoma care. As with all children, it is best to start simply and add steps as needed. With adolescents, extra ostomy products that might eventually be useful, along with clearly written directions and indications for use, can be given in advance. They can make the decision to add the products later, as needed.
- Managing oily skin may become an issue if pouch adhesion is diminished.
- A greater selection of pouches are generally available on the market for adolescents than for younger children. Pre-cut pouches are easy for self care if the adolescent has a round stoma and the stoma size has stabilized.
- Wear time is generally two to five days (up to seven). Encourage the adolescent to change the pouch on a routine schedule to avoid pouch failure at embarrassing moments.
- Gas filters added onto pouches (**see Table 3**) or pouches with commercially incorporated filters may be good choices. The filter will need to be covered per manufacturer's instructions when bathing or in water to maintain its efficacy.
- Use of room and pouch deodorants should be discussed (**see Table 3**).
- Lifestyle and normal activities should be assessed to help determine the most useful pouch and accessories.

### **Pouch Selection and Ostomy Care**

**Statement:** Multiple factors need to be considered when deciding on a pouching system (ostomy appliance and accessories) for a child with an ostomy. It is also important to appreciate that caregivers, including health care personnel, may be unfamiliar with ostomy care. Choose the simplest pouching system that will be effective in protecting peristomal skin and containment of effluent.

Factors commonly considered when selecting a pouching system are:

- Size of abdomen/pouching surface and age of the child
- Type of stoma (fecal or urinary)
- Diameter and profile of stoma(s)
- If there are multiple stomas, the proximity of the functioning stoma/stomas to the nonfunctioning stomas or mucus fistula
- Abdominal contours and the proximity of the stoma/stomas to anatomical landmarks, skin folds, creases, scars, incisions, medical devices
- Volume, consistency, and corrosive nature of the effluent
- Peristomal skin integrity (intact versus denuded/weeping)
- Age-related epidermal development (i.e., premature infant versus older child)
- Abdominal muscle development (weak versus well-developed musculature)
- Age, manual dexterity, mobility, and life-style
- Product availability
- Cost

## Pouch Selection

**Education.** For pouch selection, there are several considerations that must be addressed to ensure that the ostomy appliance is effective for the size/age of the child or infant, the type of stoma, and the quantity and nature of the effluent.

One consideration for pouching is use of a wafer or barrier, with a hydrocolloid portion that directly contacts the skin. When choosing this type of appliance, consider:

- **Size:** The wafer needs to be large enough to accommodate all stomas that are to be pouching within that wafer with enough wafer remaining to secure the pouch to the skin.
- The wafer or barrier should provide a base of at least 1/2- to 1-inch radius around the stoma where possible, allowing adequate skin adhesion to support the weight of the pouch.
- **Regular-wear versus extended-wear:** Regular-wear (sometimes called standard-wear) barriers absorb more moisture and are less aggressively adhesive than extended-wear barriers. The hydrocolloid in regular-wear barriers has high “flow” or better ability to spread over the skin, which improves adhesive contact. Extended-wear barriers have delayed absorption of moisture, and may withstand high volume or liquid effluent better than regular-wear barriers. The hydrocolloid in extended-wear barriers has low “flow” and spreads over the skin more slowly, but is more aggressively adhesive. Pouches with extended-wear barriers are also more expensive than those with regular-wear barriers.
- **Presence/absence of a “starter hole”:** Most cut-to-fit wafers have a precut opening. The opening in the wafer should be no larger than the base of the stoma to avoid exposing peristomal skin to effluent. The location of the starter hole dictates stoma placement within the wafer, because the entire starter hole must be placed within the aperture cut for the stoma. If more than one stoma is pouching within a single appliance or if the pouch must be shifted away from center to avoid abdominal landmarks, then a wafer without a starter hole – found on some infant pouches – may be more appropriate.
- **Flat versus convex shape:** The shape of the barrier should be the mirror image of the peristomal plane. Flat barriers are used when the peristomal plane changes little with shifts in position and the stomal protrusion is adequate to direct effluent into the pouch. Convex barriers have an outward curve which begins at the aperture and extends outward (see Table 3). These types of barriers put pressure on the peristomal skin to increase protrusion when the stoma is flush or retracted. Convexity can also support peristomal skin when skin folds and/or creases interfere with wafer adherence resulting in an inadequate seal and pouch leakage. Convexity should be avoided with fresh post op neonates.

Another consideration is the pouch bag or containment device used to collect the effluent.

- **Color:** A clear pouch is used during hospitalization for adequate visibility of the stoma and effluent. Opaque pouches are available for use after discharge.
- **Size:** The pouch should be large enough to accommodate effluent (gas, stool, urine) without needing to be emptied too frequently, while still being appropriate to the child's size. An inactive stoma may need only a very small pouch while a very active stoma may need a larger pouch. A larger pouch may be required on an infant with significant stomal

edema, a large prolapsed stoma, or high-volume output requiring frequent pouch emptying.

- Urinary versus fecal ostomy pouches: Urinary pouches have a drain spout or tap at the distal end with a valve or plug closure. These pouches can also be connected to a urinary collection container. Urinary pouches have an anti-reflux flap to limit the backflow of urine onto the stoma, and are sometimes used for high-output fecal stomas. Fecal pouches have a large opening at the tail end to allow emptying of thicker, more formed effluent, and do not have an anti-reflux flap. Pouch closure is generally added, although some have a pouch closure incorporated into the pouch.
- Closed-end versus drainable (open-end) pouch: Closed-end pouches are used for inactive or minimally active stomas, or stomas with formed stool and limited evacuations per day. Closed-end pouches must be removed or cut open in order to empty effluent, which makes them generally not practical for use in the hospital. Drainable pouches have a large opening at the distal end or tail to allow periodic emptying.
- One-piece pouches are manufactured with the wafer and pouch incorporated as a single unit. They are low profile, flexible, and require fewer steps for application. Two-piece pouches have a wafer as a separate unit from the pouch. This allows for removal of the pouch without removal of the wafer/barrier. Two-piece pouches may have:
  - A rigid, snap-together flange or coupling to join the wafer and pouch securely, or an adhesive coupling to join the wafer and pouch securely. The rigidity of the connecting parts precludes their use on premature infants and full-term neonates with weak abdominal musculature, children with recent abdominal surgery, or children with a prolapsed stoma, unless the two pieces are snapped together first and applied as a unit, or the wafer has a 'floating flange' which allows attaching the pouch without applying pressure on the abdomen.
  - A flexible adhesive joining the wafer and pouch rather than plastic rings may be used on infants and children. The adhesive coupling wafer and pouch must be used as a unit and are not interchangeable with snap together pouch/wafer systems.

## Ostomy Care

**Education.** Ostomy care includes the emptying and application of the ostomy appliance, and the care of peristomal skin and the stoma. Ostomy care episodes are important times to observe the peristomal skin and to address any problems.

### Emptying the ostomy appliance.

- Empty the pouch when one-third to one-half full. The pouch fullness includes the total measure of gas, urine, or stool within the pouch.
- Allowing the pouch to fill beyond one-third to one-half full increases the weight of the pouch and may result in pouch failure.
- Fecal effluent can be emptied by massaging or "milking" the stool from the pouch into the toilet or diaper during regular diaper changes. If output is being measured, it may be emptied into a measuring container.
- When effluent is liquid, including stool, a urostomy-style pouch with a tap or drain spout can be used. Infant urostomy-style pouches can be emptied by withdrawing effluent from the pouch with a syringe, or with the straight drainage attachment. The anti-reflux device present inside many urostomy pouches may need to be disabled to allow solid stool

particles to pass into the distal pouch. A finger placed into the aperture of the wafer can gently separate the anti-reflux valve from one wall without damaging the pouch.

- The pouch can be angled to the side of the patient for easier emptying. Angling the pouch to the lateral side facilitates emptying into a diaper. Angling the pouch toward the crotch makes emptying easier if a child is ambulatory and can sit on a toilet.
- Rinsing a pouch after emptying while it is still being worn is not recommended. This may loosen the wafer, decreasing wear-time.
- With fecal pouches, wipe inside the tail above the level of the pouch closure to prevent stool from leaking out when the pouch is closed. This will prevent soiling and odor. Toilet paper or commercial infant wipes can be used for this purpose.
- When the pouch has been emptied, re-clasp the pouch closure.
- gas filter may be added to a pouch that continually fills with flatus, particularly if the gas exerts enough pressure on the pouch to cause premature failure of the wafer seal. Some pouches already have an integrated filter. Once a filter becomes wet with liquid effluent it will no longer filter odor.

**When to change an ostomy pouch.** Ideally, a child's appliance should be able to remain in place for up to four days. Wear-time can vary, however, in different age groups. Average wear-time on an infant with an established stoma may be two to three days, but on the premature infant is likely to be shorter due to sub-optimal stomas, multiple stomas, small pouching surfaces, and other factors. On a premature infant, goal of wear time may be 24 hours with acceptable wear times ranging from 12 to 48 hours (Rogers, 2003). Acceptable wear-time for the infant may initially be 12 to 24 hours. Adolescents sometimes achieve longer wear-time, but the pouch should be changed at least every seven days to inspect the stoma and peristomal skin.

**NOTE:** New-onset problems with pouch adherence may indicate malabsorption of enteral feedings or gastrointestinal infection. Fecal effluent in malabsorption states becomes more liquid, and changes occur in the chemical composition and pH of the stool. This results in more rapid erosion of the barrier and reduced ability to maintain adhesion.

Remove and replace an ostomy appliance immediately if the wafer shows signs of undermining, such as effluent tunneling under the pouch wafer, even for a short distance. Other signs of impending leakage include: odor from the stoma, even when the pouch is closed; visible erosion of the pouch wafer, particularly around the stoma, which is also known as "melt down"; and effluent on skin, dressings, clothing, or bedding that is not due to leakage from the pouch tail.

Never "patch" a leak to prolong pouch wear-time. Effluent can quickly damage peristomal skin. Children with peristomal skin damage, skin infection, open wounds beneath the wafer, or large volume liquid or caustic effluent should have their pouch changed a maximum of every two days. This allows observation of the peristomal area and treatment of complications.

Routine pouch changes before expected wafer failure (based on previous experience with the stoma) may help prevent leakage and subsequent skin damage. Careful inspection of the removed wafer at each pouch change will help guide the frequency of changes of the pouching system. Pouch changes can be planned when the stoma is quiet and scheduling is less hectic.

**Removing an ostomy appliance.** Removal of a pouch should be done gently to avoid mechanical trauma of the peristomal skin. Steps include:

1. Dampen a soft, lint-free cloth, paper towel or gauze with warm water.
2. Lift the edge of the pouch wafer with one hand. Gently push down to separate the peristomal skin from the wafer with the damp cloth or a finger. Do not pull the pouch wafer off the skin. Skin irritation or epidermal stripping may occur.
3. Soap, while not recommended for routine use, contains surfactant that may help decrease adhesion of the wafer to the skin. If used, the soap should be rinsed thoroughly from the skin before applying a new pouch.
4. Adhesive removers/solvents can aid removal of a particularly adherent pouch wafer. Use is not recommended routinely on infants due to safety issues (see Table 3). If used, it should be removed from the skin immediately with soap and water to limit transepidermal absorption of chemicals.
5. Remnants from the pouch wafer that remain on the skin after removal do not usually interfere with adhesion of the new pouch and do not need to be vigorously removed. Aggressive removal may damage the skin.

**Peristomal skin/stoma care during pouch change.** Care of the peristomal skin and stoma should be performed gently. The skin may be fragile and easily damaged, particularly in a premature infant or poorly nourished child. Fecal stomas lack somatic afferent nerve endings responsible for transmitting pain signals, and pain may not be perceived with overly vigorous handling. The stoma is also highly vascular and may bleed easily with cleaning or with manipulation.

A second caregiver may be required during stoma care to distract or restrain an infant or young child, who, if very active, can damage the stoma or disrupt the pouch change (Colwell, Goldberg, & Carmel, 2004). If help is unavailable, limbs may be restrained or splinted by other means (such as swaddling with a blanket).

After pouch removal, peristomal skin should be cleansed using warm water and a soft, lint-free cloth. Paper towels are sometimes useful for this purpose and are disposable.

As previously noted, use of soap to cleanse peristomal skin is not necessary. If soap is used, it should be free of additives (antimicrobials, perfumes, deodorants, lotions) to prevent chemical dermatitis or interfere with pouch adhesion. The skin should be rinsed thoroughly prior to applying new pouch.

Commercial infant wipes should not be used for cleansing peristomal skin because they contain lanolin or other emollients that may decrease pouch adhesion. Some commercial infant wipes contain alcohol which can dry and irritate the skin and is absorbed transepidermally. In addition, most contain fragrances that could topically sensitize the skin beneath the pouch, and can change the skin pH.

While a small amount of bleeding with stoma manipulation is normal, continuous bleeding or bleeding from the stoma opening is abnormal and must be reported to the surgeon.

Dry the skin around the stoma thoroughly prior to pouch application for optimum adhesion. The pouch wafer will not adhere to damp skin. A hairdryer on “cool” setting, although used by



some caregivers to dry peristomal skin prior to pouch application, presents a risk of burning the skin and is not recommended.

If the stoma is active (continues to produce effluent) during pouch change, output can be contained with an absorptive dressing, such as gauze, or lint-free cloth wrapped around the stoma. A “wick” created from rolled toilet paper or facial tissue may also be used to wick or blot effluent at the stoma. The absorptive or wicking material should be removed immediately prior to applying a new pouch to prevent effluent from leaking onto the skin and being trapped under the barrier.

During the pouch change, observe/chart the following:

- Stoma color.
- Stoma size (diameter), shape (oval, round, or irregular), and structure (flush, spout, mushroom, pro- lapse) as well as viability of stoma(s).
- Presence of bleeding.
- Presence of lacerations (may look like white line near base of stoma) or other lesions.
- Integrity of the mucocutaneous junction (area where stoma mucosa borders peristomal skin). Sutures may be visualized at the junction if stoma is new within past few days to two to three weeks.
- Volume, character and color of output.
- Peristomal skin condition and contours including creases, depressions, irritation or superficial skin loss (denudement), presence of rash, character of peristoma wounds (see **Table 4**).
- Pouch change date and time, reason for change, and location of leakage/tunneling of effluent, if present.

**Cutting the stoma aperture.** Cut-to-fit pouches are generally used on children because of the variations in stoma size postoperatively and with normal physical growth. This requires measuring and cutting an opening on each pouch barrier to fit the stoma(s). Generally, multiple intestinal stomas may be pouched within the same appliance, with exceptions (see “**Pouch Selection and Ostomy Care, Ostomy Care, Education., Care of the mucous fistula.**” section). Urinary and intestinal stomas should always be pouched separately, except at the discretion of the surgeon.

Stomas decrease in size over six to eight weeks postoperatively and must be re-measured with each pouch change until their size has stabilized. Stomas created to correct or alleviate conditions in which the bowel is dilated (i.e., Hirschsprung’s disease) will experience greater decrease in size as the bowel decom- presses.

Physical growth causes an increase in stoma size. Stomas should be re-measured weekly in a growing child, and whenever a previously adequate pouching system begins to fail. A stoma-measuring device (included in each box of pouches) should be used to measure stoma size at the level of the mucocutaneous junction to determine the size aperture to cut in the pouch wafer.

The aperture for the stoma should be no more than 1/8-inch in diameter larger than the stoma diameter at skin level to minimize skin exposure to effluent, and no less than equal to the stoma diameter to prevent trauma to the stoma or obstruction of the stoma opening.

Using a template or stoma measuring device, trace the correct size opening onto the paper backing of the pouch wafer. The opening for the stoma can be centered on the wafer, or away from center if the pouch would benefit from being shifted from landmarks on the abdomen (i.e., umbilicus, groin, ribs, incision, drains or other tubes, hip bone).

If the wafer has a pre-cut starter hole, the tracing for the stoma opening must encompass the entire starter hole to prevent excess skin exposure to effluent. Pre-cut starter holes limits the ability to shift the pouch away from abdominal landmarks. If using an appliance with a starter hole, and the hole is not in the best location for the stoma, it can be covered from inside the pouch, or on top of the wafer if a two-piece system, with a piece of hydrocolloid dressing or the remnant left from cutting the new stoma opening.

Irregularly shaped stomas, grouping of stomas, or stoma(s) in close proximity to abdominal landmarks may require a custom template or tracing. To make a template:

1. Place a sheet of transparent, flexible plastic or cellulose over the abdomen, and trace the stoma base and other landmarks onto the plastic with a felt-tip marker.
2. Label tracing with arrows indicating head and foot, “pouch side” (side facing the caregiver), and “skin side” (side resting on the patient’s skin) to prevent pattern reversal.
3. This pattern can be cut and then traced onto a pouch wafer, taking care not to reverse the pattern. The wafer is then cut to fit.
4. If the pouch will be worn angled to the side rather than toward the feet and the stoma shape is not round, the template should be angled on the pouch to mirror the relationship of the pouch to the stoma/abdomen prior to tracing the stoma opening on the paper backing of the wafer.
5. Before cutting the stoma aperture, pull the pouch front away from the wafer, creating a pocket of air between the wafer and the pouch front. This minimizes the risk of puncturing the pouch while cutting. Use a small pair of rounded-tip scissors to cut the aperture.

Before removing the paper backing from the pouch wafer, place the wafer over the stoma(s) to determine that the stoma opening is a correct fit. Also assess if any of the wafer will need to be trimmed away to accommodate groin movement, the moist umbilicus of a newborn, or any medical devices that may be in close proximity to the ostomy. Trim the opening as needed, refitting the wafer over the stoma(s) with each correction, until the opening is the correct size and shape to fit the stoma(s). Take care not to cut away too much of the wafer with each correction, or the opening may become too large, exposing peristomal skin, and the pouch will not be useable. Rub the cut edge of the stoma hole with a finger to smooth rough edges.

**Preparing/leveling the peristoma skin surface prior to pouch application.** Pouches adhere best when placed onto a level skin surface. Irregular peristomal skin surfaces can be leveled prior to pouch application using a variety of accessory ostomy products and/or a flexible one piece appliance. Peristoma skin should be clean and completely dry when applying the pouch to improve adhesion (see “**Pouch Selection and Ostomy Care, Ostomy Care, Education., Peristomal skin/stoma care during pouch change.**” section).

A flat surface allows for better pouch adhesion. A variety of accessory ostomy products may be used to fill in, or level, uneven skin surfaces (skin creases, incisions, parastomal hernias, scars, retention rods) beneath the barrier prior to applying the pouch. If developmentally appropriate, have the child sit, stand, and bend to assess changes in the peristomal plane.



When assessing an infant, bend the knees up towards the abdomen and lift the head up as in the cuddle position to assess creases and contours.

The pouching surface can be leveled in several ways:

- Skin creases and folds can be filled with pieces of barrier supplements/strips (see Table 3). These substances are similar in composition to pouch wafers although are more moldable.
- Barrier supplements/strips/rings can be applied circumferentially around the stoma in order to smooth an abdominal surface with multiple irregularities. Or, barrier supplements/strips can be placed directly onto the pouch wafer around the stoma opening, after removing the paper backing from the wafer.
- Skin barrier (stoma) paste can be used in small amounts to fill uneven surfaces. Routine use of paste on infants, particularly premature infants, is strongly discouraged due to its chemical content and aggressive adhesion. When other options for maintaining pouch adhesion fail, its use may be considered, with precautions.
- Complex problems causing irregularities of the peristomal plane, such as dehiscent wounds, may need to be referred to an WOC(ET) nurse.

Liquid skin barrier is sometimes applied to peristomal skin to protect it from damage caused by effluent tunneling under the barrier. Routine use of liquid skin barrier on the peristomal skin, however, is discouraged. Its use may prevent the hydrocolloid (wafer) from absorbing water and decrease the wafer seal. Its use may be considered, with precautions (see Table 3).

**Applying the pouch.** Warm the pouch wafer between two hands or next to a skin surface, or place under a recumbent child to soften the wafer and increase its flexibility and adherence. After cutting opening, remove the paper backing on the pouch wafer. The paper backing can be saved as a template for cutting the next pouch. Also remove any gauze that may have been placed around the stoma to keep the peristomal skin dry.

Apply the pouch to the prepared skin surface, centering the opening directly over the stoma and angling the pouch tail toward the feet or slightly to one side. Angling the pouch to the lateral side improves drainage away from the stoma when a child, particularly an infant, is in the recumbent position. Angling the pouch toward the groin makes emptying easier if the child is ambulatory and can sit on a toilet to empty the pouch. Pouch application should be done quickly if the stoma is active to prevent effluent from leaking under the wafer.

Alternative steps for applying a pouch with a very active stoma are:

1. Tear the paper backing in two or three places, from the aperture to the outer edge of the wafer.
2. Leaving the paper in place, fold an edge of each paper section back as a “pull-tab.” Once the pouch is in place over the stoma, grasp the pull-tabs and remove each section of paper. In this way, the barrier is protected from moisture (effluent) that may prevent an adequate seal.

Check that no part of the stoma is trapped beneath the pouch wafer. With the fingers, press the wafer into place beginning at the stoma and working to the outer edge, and circumferentially around the wafer. As- sure that all air bubbles and wrinkles are removed and good contact is achieved with the skin.

Place a hand (or hands) over the wafer for 1 to 2 minutes, applying pressure and warming the barrier. This enhances the barrier adhesion.

To enhance adhesion, the child should avoid strenuous movements for 30 minutes following a pouch application. This is the critical period during which barrier flow occurs.

Finally, close the end of drainable pouches using the appropriate pouch closure for either fecal ostomy or urostomy pouches.

**Care of the mucous fistula.** A mucous fistula may not require pouching unless there is associated discharge, or pouching is required to protect the stoma. Considerations for care include:

- Cover the mucous fistula to prevent drying out, particularly on an infant under a radiant warmer. A non-adherent dressing or adhesive bandage, applied dry or with a small amount of water soluble lubricant, may be adequate.
- Application of petrolatum to the dressing or use of petroleum-impregnated gauze, while keeping the stoma moist, may migrate onto the skin and interfere with pouch adhesion around the functioning stoma. If petrolatum is applied to prevent adhesion of the dressing to the mucous fistula, only a minimal amount should be used. Petrolatum should be discontinued if pouch adhesion is affected.
- The mucous fistula may be left uncovered within an infant's diaper, if placement is lower than the functioning stoma and the infant is not at risk of handling the stoma. Irritation or bleeding of the mucous fistula due to friction from the diaper in an active infant may necessitate covering the stoma.

If the mucous fistula is positioned above the functioning stoma or if the volume of secretion is high, mucous secretions from the stoma may decrease pouch adhesion around the functioning stoma. Pouching may become mandatory to contain secretions. Generally, the mucous fistula may be pouched within the same appliance as the proximal or functioning stoma.

In some circumstances, the mucous fistula should be pouched separately from the functioning stoma, including:

- Following repair of anorectal malformations, if stomas are spaced far enough apart on the abdomen to allow separate pouching of the functioning stoma. This prevents spill-over of stool from the functioning stoma into the mucous fistula, which would result in contamination the surgical anastomoses (see **Table 1**).
- Presence of a fistula between the distal limb of bowel and the urinary tract. Separate pouching of the mucous fistula prevents cross-contamination of the urinary tract with feces.

## Discharge Planning

**Statement:** Discharge planning, whether the ostomy is temporary or long-term, must prepare the family for caregiving, and involve the child whenever possible with developmentally appropriate tasks.

## Infant

**Education.** Many infant ostomies are temporary and some may be closed before the infant's health and growth allow for hospital discharge. Some infants, however, will be discharged home with their stoma in place. Preparing the family to care for an infant with a stoma in the home must be undertaken well before discharge.

Steps to help prepare the family to care for an infant at home include:

- Involve parents or caregivers in hands-on stoma care as soon as the infant's condition is stable. This facilitates bonding with the infant and promotes the development of skills necessary to manage the stoma after discharge, while nurses experienced in ostomy care are still available to supervise and act as role models.
- A written discharge teaching checklist for ostomy care is helpful to plan and track needs prior to discharge. Areas to be covered include:
  - Reason for ostomy surgery and type of ostomy.
  - Emptying and putting on a new pouch.
  - Usual stooling pattern/consistency, as well as how often to empty pouch.
  - Special dietary modifications, if needed.
  - Medications, their affect on the ostomy, and possible side effects.
  - Potential stoma problems.
  - Signs and symptoms of complications depending on the type of ostomy such as obstruction, dehydration, constipation for fecal diversions or urinary tract infection for urinary diversions.
  - Guidelines for seeking medical care.
  - Supplies needed for stoma care.
  - Where and how to obtain supplies.
  - Resources for families.
- Written instructional materials given to the parents can be helpful after discharge when health care personnel are not readily available to answer questions. In addition to the pediatric ostomy educational handouts typically supplied by your hospital, other excellent handouts include:
  - A Parent's Guide to Ostomy Care for Infants and Children, by ConvaTec (Princeton, NJ)
  - What's Right for My Baby?, by Hollister Incorporated (Libertyville, IL)
  - Life After Your Child's Ostomy Surgery; for Newborns, for Pre-Schoolers, for School-Age, by Coloplast Corporation (Minneapolis, MN)
- A written list for the family of names and phone numbers to call with questions regarding ostomy care including a Wound, Ostomy, Continence [WOC(ET)] nurse.

(For other sources of ostomy information and support organizations for caregivers, see **Appendix A**).

Other helpful considerations for the family include a pre-discharge visit from a member of the United Ostomy Association. Home nursing visits should also be arranged as indicated. Arrange for home ostomy supplies, or instruct caregivers on how to obtain supplies. (Prescriptions may be necessary for health insurance coverage of supplies.) Discharge the infant home with adequate ostomy supplies to last until home delivery is instituted.

Other topics to discuss prior to discharge include: sibling preparation, traveling with an infant who has an ostomy, and daycare/babysitting arrangements.

### **Toddler/Preschooler**

**Education.** Parents should observe and then do at least one complete pouch change and pouch emptying before discharge. Discuss with parents signs and symptoms of complications depending on the type of ostomy such as obstruction, dehydration, prolapse, constipation for fecal diversions or urinary tract infection for urinary diversions.

Preparation/education should be directed toward the parents, while the toddler is encouraged to help with small tasks. Helpful tools and teaching aids include “Shadow Buddy” (provided by Hollister Incorporated), or stuffed animals that can be used to teach young children. “Shadow Buddies” can also be used to teach siblings. Other resources helpful include the UOAA coloring book, “Chris Has an Ostomy”; “My Child Has an Ostomy”; “A Parent’s Guide to Ostomy Care for Infants and Children” (ConvaTec, Princeton, NJ); “Can they Still Wiggle and Giggle?” (Hollister Incorporated, Libertyville, IL); Life After your Child’s Ostomy Surgery; for Newborns, for Pre-schoolers, for School Age Children (Coloplast Corporation, Minneapolis, MN); and the Pull-thru Network (<http://www.pullthrunetwork.org>).

Parents and children may “name” the stoma as a way of coping with stoma or to establish a means of communication when in public if child has a concern about their ostomy pouch but too shy to say something. For example, “Mom, I think Rosie needs you to check on her.”

### **School-Age**

**Education.** The school-age child needs to have an ostomy care kit, including a prepared pouch ready at school. Parents should meet with the school nurse to discuss ostomy care needs at school, determine a plan for care, and provide the school nurse with a resource phone number in case of questions (Colwell et al., 2004) (Wong & Hockenberry, 2003).

Other helpful hints include:

- Set up a schedule to empty the pouch at school in private.
- Have the child keep an extra set of clothes at school.
- It is important for parents to be comfortable with their child’s ostomy care. Encourage the child to participate with the care, gradually increasing the tasks the child does in the pouch change process.
- It is important for family to return pouch demonstration.
- With a long-term stoma, increase the child’s participation as he/she is able.
- Approaching teaching the child as play to facilitate confidence building. Allow child to play with sample pouch, a stoma model made from play dough, a “Shadow Buddy” doll also can be a helpful tool.
- Home health referrals will assist with teaching reinforcement and troubleshoot pouching problems.

### **Adolescent/Teenager**

**Education.** Prior to discharge, an adolescent or teenage patient should be able to demonstrate the following skills:

- Empty and correctly change pouch.
- Prepare a kit with the necessary supplies.
- Be able to state the minimum fluid requirements for urostomy and ileostomy, as well as signs of de- hydration and how to correct hydration. Be able to state the signs and symptoms of obstruction, early treatment methods and when to contact their physician.
- Be able to state how often to change pouch; how to order supplies; and any “rules” for supplies (authorization, have to call in each month).
- Reference a list of gas-causing foods and fluids; high-fiber foods that can cause an obstruction (ileostomy), and those foods and fluids that cause odor (urostomy).
- Be able to review plans for bathing/showering, swimming, and sports; such as timing of pouch emptying and change, need for special belt, leg bag, etc.

The child and their parents should discuss potential problems, such as pouch leaks with the school nurse. Encourage the teen and parent to discuss who needs to know about the ostomy at school, and discuss how to inform others if this is important to the teen. Role-playing may be required to help the teen initiate these conversations. Participating in gym class and public showers should also be discussed.

For events such as overnight stays, travel and camping, a plan needs to be developed. Make sure the adolescent/teen has emergency supplies, pre-cut and prepared, including paper towels. A small cloth container or resealable disposal bag can be used to organize emergency supplies. A disposable storage bag (“Baggie”) may help for disposal of used pouch.

Encourage participation of pre-teen and teen patients in Youth Rally Ostomy Camp (Youth Rally Committee, 2010).

Teens should be encouraged to be independent in providing self-care if capable. They should be given the opportunity to do pouch changes, pouch emptying, and re-clamping. In particular, teens need to know step-by-step procedures for emptying the pouch into the toilet. (Some may prefer to straddle toilet seat. Placing toilet paper in the water will decrease splash. After emptying pouch, cleanse stool from tail with toilet paper, wipe, or paper towel to reduce risk of odor once closed. Close bottom.) Parents need to be included in discussion and demonstrations.

It may be helpful and supportive for adolescent to meet another teen who has a stoma. With parental approval, email and other communication may be arranged.

**Table 1. Surgical Indications for Fecal Diversions**

Condition/Disease	Description	Age Group Affected	Type of Stoma	Permanent vs Temporary
<p>Anorectal Malformations</p> <p>Includes:</p> <ul style="list-style-type: none"> <li>• Imperforate Anus</li> <li>• Persistent Cloaca</li> </ul>	<ul style="list-style-type: none"> <li>• Congenital malformation encompassing anomalies of rectum and urinary and reproductive structures. Fistula or communication with perineum or other GI/GU structures is common. Anal opening may be absent.</li> <li>• May occur as a component of VAC- TERL association: V=vertebral anomalies, A=imperforate anus, C=cardiac anomalies, T=tracheoesophageal fistula, E=esophageal atresia, R=renal anomalies, L=limb anomalies.</li> <li>• Classified as “high” or “low” defect, depending on location of defect above or below the pelvic floor muscles. High defects require more extensive surgical correction and have a poorer prognosis for continence.</li> <li>• Stoma is created emergently if infant is unable to pass stool, or when fistula results in fecal contamination of urinary tract.</li> <li>• Surgical correction is posterior sagittal anorectoplasty (PSARP) or “pull-through.” If not already present, stoma may be created to divert stool from surgical site. As child grows, stoma may become necessary due to failed surgical correction including severe anal stricture, massive colonic dilatation, and intractable incontinence.</li> </ul>	<ul style="list-style-type: none"> <li>• Newborn, if bowel obstruction, GI/GU fistula</li> <li>• Infant, following PSARP</li> <li>• Toddler, preschool, school-age or adolescent with surgical failure, bowel decompensation</li> </ul>	<ul style="list-style-type: none"> <li>• Colostomy (see <b>Glossary</b>)</li> <li>• Ideally two stomas: functioning stoma and a mucous fistula separated by adequate skin to pouch separately (prevents fecal contamination of surgical anastomoses)</li> <li>• May also be loop stoma or double-barrel stoma brought through the same incision</li> <li>• Cecostomy or appendicocostomy in cases where bowel management necessitates colonic irrigations: may also be called an ACE stoma or Antegrade Continence Enema stoma</li> </ul>	<ul style="list-style-type: none"> <li>• Temporary after PSARP, with closure typically three to six months postoperatively, following serial anal dilatations</li> <li>• Generally temporary when created for failed repair, but may be permanent</li> </ul>

**Table 1. Surgical Indications for Fecal Diversions**

<b>Condition/Disease</b>	<b>Description</b>	<b>Age Group Affected</b>	<b>Type of Stoma</b>	<b>Permanent vs Temporary</b>
Chronic Intestinal Pseudo-Obstruction (CIP)	<ul style="list-style-type: none"> <li>• Rare disorder of intestinal motility in which peristalsis becomes altered and inefficient. May be neurogenic (unsynchronized contractions) or myogenic (weak, absent contractions). Intestines react as though there is mechanical obstruction, without physical evidence of block- age. Congenital and acquired forms. Symptoms include abdominal distention and pain, intractable constipation, malnutrition, and recurrent intestinal bacterial infections.</li> <li>• Treatment generally medical, including total parenteral nutrition (TPN) and antibiotics. Bowel resection or small bowel transplant in severe cases.</li> </ul>	<ul style="list-style-type: none"> <li>• Congenital: infant</li> <li>• Acquired: all ages</li> </ul>	Ileostomy	<ul style="list-style-type: none"> <li>• Generally temporary</li> <li>• May be permanent</li> </ul>
Cloacal Exstrophy (see <b>Glossary</b> )	<ul style="list-style-type: none"> <li>• Rare congenital malformation which includes omphalocele, two exstrophied hemi bladders, prolapsed bowel, imperforate anus, and abnormalities of the genitalia. Frequently associated with myelomeningocele and other anomalies.</li> <li>• May require staged surgical reconstruction.</li> </ul>	Newborn, with lifelong sequelae	<ul style="list-style-type: none"> <li>• Fecal: colostomy or Ileostomy</li> <li>• Urinary: see <b>Table 2</b></li> </ul>	<ul style="list-style-type: none"> <li>• Fecal: generally permanent</li> <li>• Urinary: see <b>Table 2</b></li> </ul>
Chrohn's Disease	<ul style="list-style-type: none"> <li>• Predominantly full-thickness inflammatory disease of the bowel affecting any segment of the alimentary canal, from mouth to anus. Normal, unaffected areas often separate diseased areas, called "skip lesions."</li> <li>• Surgery is not curative and is avoided until medical management is unsuccessful at controlling life-threatening complications.</li> <li>• Complications that can lead to creation of an ostomy include bowel perforation or stricture, abscess, fistula, perianal disease, toxic megacolon, and massive hemorrhage.</li> </ul>	All ages of children; but primarily older school-age, and beyond	Ileostomy	<ul style="list-style-type: none"> <li>• Generally temporary</li> <li>• May be long-term temporary or permanent if fecal diversion does not control complications (i.e., severe perianal disease, multiple enteric fistulas, recurrent abdominal, or pelvic abscesses)</li> </ul>



**Table 1. Surgical Indications for Fecal Diversions**

<b>Condition/Disease</b>	<b>Description</b>	<b>Age Group Affected</b>	<b>Type of Stoma</b>	<b>Permanent vs Temporary</b>
Familial Adenomatous Polyposis (FAP)	<ul style="list-style-type: none"> <li>• Rare, inherited disorder characterized by the development of multiple polyps in the colon or other organs. Development of cancer is nearly 100% within 15 years of the appearance of polyps, which usually occurs during adolescence.</li> <li>• Prophylactic total proctocolectomy is advised soon after diagnosis to prevent malignant changes. Commonly, surgical creation of an ileoanal reservoir (IAR), also known as an ileal pouch anal anastomosis (IPAA) or j-pouch, achieves continence.</li> </ul>	Adolescent	Ileostomy	<ul style="list-style-type: none"> <li>• Temporary until surgical anastomoses have healed, at least six weeks following IAR/IPAA.</li> <li>• Radiographic confirmation of j-pouch patency generally obtained prior to stoma closure</li> </ul>
Hirschprung's Disease	<ul style="list-style-type: none"> <li>• Congenital absence of ganglion cells in the distal intestine, extending proximally from the anus. Normal peristalsis cannot occur in the aganglionic segment of bowel, leading to functional obstruction of stool.</li> <li>• Up to 10% of patients have total colonic aganglionosis, with absence of ganglion cells in the entire colon and varying amounts of small bowel.</li> <li>• Surgery, called a "pull-through" procedure (Soave, Duhamel or Swenson), is performed to remove the aganglionic segment. During the newborn period, this surgery may be done with or without the creation of a stoma.</li> </ul>	<ul style="list-style-type: none"> <li>• Newborn, infant, toddler, preschool</li> <li>• Rarely school age, adolescent</li> </ul>	<ul style="list-style-type: none"> <li>• Colostomy</li> <li>• Ileostomy with total colonic aganglionosis</li> <li>• Cecostomy in cases where bowel management necessitates colonic irrigations</li> </ul>	<ul style="list-style-type: none"> <li>• Temporary, with closure performed at the time of the pull-through surgery</li> <li>• May be permanent if associated with bowel dysmotility</li> </ul>
Intestinal Atresia's <ul style="list-style-type: none"> <li>• Duodenal</li> <li>• Jejunal</li> <li>• Anal (see <b>Anorectal Malformations</b>)</li> </ul>	<ul style="list-style-type: none"> <li>• Complete disruption of the lumen of the bowel. Usually occurs in the small bowel. One-fifth of these infants will have more than one atresia.</li> <li>• Duodenal atresia results from failure of the bowel lumen to re-open during early fetal development. Associated with Down's syndrome.</li> <li>• Jejunal atresia results from intrauterine ischemic injury to the bowel.</li> </ul>	Newborn	<ul style="list-style-type: none"> <li>• Jejunostomy or ileostomy, with mucous fistula</li> <li>• Stomas may not be matured</li> </ul>	<ul style="list-style-type: none"> <li>• Permanent stoma generally not required</li> <li>• Temporary in unstable infant with bowel perforation, peritonitis, vascular compromise or meconium ileus</li> </ul>



**Table 1. Surgical Indications for Fecal Diversions**

<b>Condition/Disease</b>	<b>Description</b>	<b>Age Group Affected</b>	<b>Type of Stoma</b>	<b>Permanent vs Temporary</b>
Intestinal Transplant	<ul style="list-style-type: none"> <li>• Performed most commonly in children with short bowel syndrome or intestinal failure when other treatments are not successful.</li> <li>• Short bowel syndrome, in which the absorbing surface of the small intestine is inadequate to sustain life, can result from malrotation with midgut volvulus, necrotizing enterocolitis, Crohn's disease, gastroschisis or trauma, among others. Microvillous disease and intestinal pseudo- obstruction represent disorders of intestinal failure.</li> <li>• Small bowel may be transplanted alone or in conjunction with a liver, as in the case of TPN-induced liver disease. It may also be part of a multi- organ transplant, as in children with severe pseudo- obstruction. Stoma provides portal for frequent endoscopic surveillance of the graft.</li> <li>• Complication rate is high and includes bowel perforation, rejection, graft vs. host disease and infection. Children must remain on immunosuppressive therapy for life.</li> </ul>	60% to 70% of small bowel transplants are done on children 18 years old and younger, including infants	<ul style="list-style-type: none"> <li>• Ileostomy</li> <li>• Gastrostomy with a gastro-jejunal tube used for enteral feeding</li> </ul>	<ul style="list-style-type: none"> <li>• Ileostomy: temporary. Usually closed six to 12 months following transplant</li> <li>• Jejunostomy: temporary, until all nutrients can be consumed through the enteral route</li> </ul>

**Table 1. Surgical Indications for Fecal Diversions**

Condition/Disease	Description	Age Group Affected	Type of Stoma	Permanent vs Temporary
<p>Intra-abdominal processes, including:</p> <ul style="list-style-type: none"> <li>• Appendicitis, perforated</li> <li>• Intussusception</li> </ul>	<ul style="list-style-type: none"> <li>• Appendicitis: Acute inflammation of the vermiform appendix, rapidly leading to perforation and peritonitis if undiagnosed. Pelvic abscess and friable bowel are typical with late presentation of perforated appendicitis.</li> <li>• Percutaneous abscess drainage and intravenous antibiotics allow recovery of bowel prior to appendectomy. Creation of stoma, although rare, may be performed in the event of bowel obstruction or failure to defervesce with abscess drainage.</li> <li>• Intussusception: Surgical emergency caused by prolapse of bowel into the lumen of an adjacent segment. Results in obstruction and ischemia of the involved bowel</li> <li>• Reduction of intussusception may be performed by enema (air or barium) or surgically. Necrotic bowel or irreducible intussusceptum are excised, generally with primary anastomosis. Stoma creation, although unusual, is performed in an attempt to preserve bowel length with extensive ischemia and in hemodynamically unstable patients.</li> </ul>	<ul style="list-style-type: none"> <li>• Appendicitis: all age groups</li> <li>• Intussusception: Infant, Toddler</li> </ul>	<p>Illeostomy</p>	<p>Temporary</p>
<p>Malrotation with Midgut Volvulus</p>	<ul style="list-style-type: none"> <li>• Malrotation results from failure of the bowel to complete its normally well-organized rotation as it re-enters the abdomen by the 10th week of gestation. The normal, broad-based fixation or anchoring of the bowel does not occur, leaving the bowel to float freely around its lone blood supply, the superior mesenteric artery (SMA).</li> <li>• Volvulus occurs as peristalsis causes the midgut, including most of the small bowel and part of the colon, to twist around the SMA. This results in complete disruption of the blood supply with rapid bowel necrosis and death.</li> <li>• Stoma is created when the bowel remains ischemic at the ends of the resected intestine.</li> </ul>	<p>Generally infant, but can occur at any age</p>	<ul style="list-style-type: none"> <li>• Typically jejunostomy</li> <li>Mucous fistula may be created to observe bowel viability</li> </ul>	<ul style="list-style-type: none"> <li>• Typically jejunostomy</li> <li>• Temporary, with closure after inflammation resolves</li> <li>• Long-term if bowel loss results in short bowel syndrome</li> </ul>

**Table 1. Surgical Indications for Fecal Diversions**

<b>Condition/Disease</b>	<b>Description</b>	<b>Age Group Affected</b>	<b>Type of Stoma</b>	<b>Permanent vs Temporary</b>
Meconium Ileus	<ul style="list-style-type: none"> <li>• Caused by an abnormality of mucous production. Thick, sticky meconium is produced that obstructs the lumen of the small bowel.</li> <li>• Stoma is created if bowel perforation and peritonitis are present, or for relief of obstruction that is not reducible with Nacetylcystine instillation.</li> <li>• 15% of cystic fibrosis patients have meconium ileus. Further diagnostic testing is indicated.</li> </ul>	Newborn	Ileostomy	Temporary
Necrotizing Enterocolitis (NEC)	<ul style="list-style-type: none"> <li>• One or more areas of intestinal necrosis interspersed with normal bowel or skip areas. A triad of events precipitates the disease, including bowel ischemia, introduction of formula or breast milk, and bacterial colonization of the gut.</li> <li>• Stoma is created if bowel perforation or gangrene develop, or for failure to respond to medical management.</li> <li>• Radiographic documentation of bowel patency is generally obtained prior to stoma closure.</li> </ul>	<ul style="list-style-type: none"> <li>• Most commonly premature infants</li> <li>• Rarely term infants</li> </ul>		Temporary, with reanastomosis no sooner than four to six weeks after initial surgery
Trauma	<ul style="list-style-type: none"> <li>• Mechanism of injury varies with developmental level, sex, and socioeconomic status.</li> <li>• Most abdominal injuries are due to blunt trauma, largely from motor vehicle accidents (MVA). Blunt trauma can result in multiple intra-abdominal injuries and cause extensive damage, including disruption of the mesentery and devascularization of large segments of bowel.</li> <li>• Penetrating injuries, most commonly from knife or gunshot wounds, are more likely to result in localized and less extensive injury.</li> <li>• Decision to operate is based on hemodynamic instability. Stomas are rarely created in children and only when extensive tissue injury necessitates bowel rest and diversion of the fecal stream.</li> </ul>	Any age, but more commonly school-age, adolescent	Colostomy, ileostomy or jejunostomy	Generally temporary

**Table 1. Surgical Indications for Fecal Diversions**

<b>Condition/Disease</b>	<b>Description</b>	<b>Age Group Affected</b>	<b>Type of Stoma</b>	<b>Permanent vs Temporary</b>
Tumor, obstructive	<ul style="list-style-type: none"> <li>• Several solid abdominal and pelvic tumors may present in childhood. Most commonly, these are Wilms' tumor, neuroblastoma, osteosarcoma, rhabdomyosarcoma, and hepatic tumors. A variety of other more rare abdominal/pelvic tumors, including germ cell tumors, may be seen. Chemotherapy, biologic therapy, radiation therapy, and surgery are the mainstays of treatment.</li> <li>• Stomas are rarely created in children with cancer, except in the presence of unrelieved obstruction of the urinary or fecal stream by tumor.</li> </ul>	All ages	<ul style="list-style-type: none"> <li>• Fecal: colostomy, ileostomy</li> <li>• Urinary: see <b>Table 2</b></li> </ul>	<ul style="list-style-type: none"> <li>• Temporary</li> <li>• Permanent if palliation required with end-stage cancer</li> </ul>
Ulcerative Colitis	<ul style="list-style-type: none"> <li>• Inflammatory changes of the rectal and colonic mucosa of unknown cause. Disease progresses proximally from the anal canal, ending abruptly at the ileocecal junction.</li> <li>• Complications that may lead to total colectomy with stoma include toxic megacolon, growth retardation, delayed puberty, massive hemorrhage, and profound malnutrition.</li> <li>• Total proctocolectomy is considered curative. Without surgery, patients have high risk of developing colon cancer. Commonly, surgical creation of an ileoanal reservoir (IAR), also known as ileal-pouch anal-anastomosis (IPAA) or j-pouch, achieves continence.</li> </ul>	School-age, adolescent	<ul style="list-style-type: none"> <li>• Ileostomy: End stoma after total colectomy. Loop stoma after creation of j-pouch</li> </ul>	<ul style="list-style-type: none"> <li>• Temporary until surgical anastomoses have healed, at least six weeks following IAR/IPAA.</li> <li>• Radiographic confirmation of j-pouch patency generally obtained prior to stoma closure.</li> <li>• Permanent in rare cases, if IAR not created or if IAR fails.</li> </ul>

**Table 2. Surgical Indications for Urinary Diversions**

<b>Condition/Disease</b>	<b>Description</b>	<b>Age Group Affected</b>	<b>Type of Stoma</b>	<b>Permanent vs Temporary</b>
Bladder exstrophy	<ul style="list-style-type: none"> <li>• A congenital defect with eversion of bladder through defect in the abdominal wall.</li> <li>• Initial management is to close the bladder and urethra and contain urinary output with ureteral stents and a suprapubic catheter. Permanent urinary diversion may be necessary in a small percentage of patients and may be delayed until after infancy (Gearhart, 1999).</li> </ul>	Newborn, Infant		
Epispadias	A congenital defect where the bladder is closed but the urethra is malformed. May need a diversion if continence is not obtained after reconstructive surgeries.	Newborn, Infant		
Cloacal exstrophy (see <b>Glossary</b> )	A congenital defect with eversion of the bowel and bladder through a defect in the abdominal wall. Genital abnormalities are present as well as an imperforate anus. Initial management is the separation of the intestinal and genitourinary systems with creation of an intestinal stoma and bladder closure. Ureteral stents and a suprapubic catheter or a vesicostomy may be used. Permanent urinary diversion may be delayed until after infancy (Gearhart, 1999).	Newborn, Infant		
Deteriorating renal function	Occasionally an infant will have severe reflux and need temporary diversion to protect the kidneys until they are older and definitive procedure can be performed, or while waiting for kidney transplant.	<ul style="list-style-type: none"> <li>• Newborn, infant</li> <li>• Toddler</li> </ul>		

**Table 2. Surgical Indications for Urinary Diversions**

<b>Condition/Disease</b>	<b>Description</b>	<b>Age Group Affected</b>	<b>Type of Stoma</b>	<b>Permanent vs Temporary</b>
Hydronephrosis	An abnormal enlargement of a kidney secondary to ureteral obstruction or chronic kidney disease. Stoma is created to relieve upper urinary tract obstruction resulting from ureteropelvic junction (UPJ) obstruction, high-grade vesicoureteral reflux or tumor. Drainage of the kidney is accomplished via open surgical or percutaneously inserted nephrostomy tube, or cutaneous ureter-ostomy (Cuckow, 1998; Joyner & Khoury, 1999). Closure of stoma or discontinuation of nephrostomy tube occurs when the underlying pathology is corrected	All ages	Nephrostomy tube or cutaneous ureterostomy	Temporary
Myelomeningocele, lipomas that compress the cord, and tethered cord conditions	<ul style="list-style-type: none"> <li>• A congenital defect in which the neural arches fail to close and expose contents of the spinal canal. Often the condition results in neurogenic bladder (a dysfunction of the bladder due to a malfunction of the autonomic nerves which control bladder function).</li> <li>• Stoma is created only if upper urinary tract deteriorates despite clean intermittent catheterization, or if family is unable to perform clean intermittent catheterization (CIC). Closure of stoma may be possible when the family or patient becomes competent and reliable with CIC, or when bladder augmentation and possibly creation of a catheterizable stoma is performed outside the infant period.</li> <li>• Rarely an ileal or colon conduit will be created in adolescence as a permanent diversion of urine.</li> </ul>	Infant, toddler, school-age child, teen	<ul style="list-style-type: none"> <li>• Vesicostomy</li> <li>• Appendicovesicostomy (APV)</li> <li>• Ileal or colon conduit</li> </ul>	<ul style="list-style-type: none"> <li>• Temporary</li> <li>• Permanent</li> </ul>



**Table 2. Surgical Indications for Urinary Diversions**

<b>Condition/Disease</b>	<b>Description</b>	<b>Age Group Affected</b>	<b>Type of Stoma</b>	<b>Permanent vs Temporary</b>
Posterior urethral valves	<ul style="list-style-type: none"> <li>• Irregular folds or leaflets of tissues that can cause urine flow obstruction.</li> <li>• Stoma is created when severe bladder outlet obstruction exists or with delayed valve ablation. Stoma is generally a cutaneous vesicostomy, but may be cutaneous ureterostomies if persistent, severe upper urinary tract dilatation is unrelieved by vesicostomy or valve ablation (Cuckow, 1998; Joyner &amp; Khoury, 1999).</li> <li>• Closure of stoma is performed after valve ablation when the infant is several months old, but may be postponed until the child is several years old, depending on renal and bladder function (Joyner &amp; Khoury, 1999).</li> </ul>	Infant	<ul style="list-style-type: none"> <li>• Vesicostomy</li> <li>• Ureterostomies</li> </ul>	<ul style="list-style-type: none"> <li>• Temporary</li> <li>• Temporary</li> </ul>
Prune belly syndrome	<ul style="list-style-type: none"> <li>• This condition is named for the wrinkly appearance of the abdominal skin caused by absent abdominal musculature. It can also be associated with undescended testes, dilated ureters and calyces, clubbed feet and heart and lung abnormalities.</li> <li>• A stoma is created in the case of recurrent urinary tract infections or renal function deterioration. The stoma is generally a cutaneous vesicostomy, but may be ureterostomies or pyelostomies if the ureterovesical junction is obstructed.</li> <li>• Closure of the vesicostomy is performed when the child grows and the bladder descends into the pelvis. Closure of ureterostomies or pyelostomies may require more extensive surgical reconstruction.</li> </ul>		<ul style="list-style-type: none"> <li>• Vesicostomy</li> <li>• Ureterostomies</li> </ul>	<ul style="list-style-type: none"> <li>• Temporary</li> <li>• Temporary</li> </ul>

**Table 3. Accessory Ostomy Products**

Many products are available to aid ostomy management and improve adhesion of ostomy appliances. It is best to start with the fewest number of products in order to simplify pouch management, and add or change products as needed to maintain healthy peristomal skin and achieve adequate pouch wear-time.

Infants, particularly premature infants, merit special consideration when adding ostomy accessories to their pouching system. They characteristically have a less-well developed epidermal barrier, greater surface- area-to-body-weight ratio, increased transepidermal absorption of substances, less mature organ function, and a less adequately developed dermal-epidermal junction than an older child or adult. These characteristics place premature infants at greater risk of sustaining injury from ostomy accessories that might be used with relative safety beyond infancy, either through transcutaneous absorption of harmful chemicals or injury to the skin with removal of aggressive adhesive products. Adding more products to obtain greater adherence to immature skin that cannot withstand their removal, and that may result in topical or systemic toxicity, can cause rather than prevent damage. In order to safeguard their health, more frequent pouch changes may be preferable to greater adhesion in the infant population.

Condition/Disease	Description	Age Group Affected	Type of Stoma	Permanent vs Temporary
Adhesives  Sometimes called: Adhesive enhancers	<ul style="list-style-type: none"> <li>• Mastisol (Ferndale Laboratories, Inc., Ferndale, MI)</li> <li>• Medical Adhesive Spray (Hollister, Inc., Libertyville, IL)</li> <li>• Nu-Hope Adhesive with applicator (Nu-Hope Laboratories, Inc., Pacoima, CA)</li> <li>• Skin Bond Cement (Smith &amp; Nephew, Inc., Largo, FL)</li> <li>• Skin Tac “H” (latex-free) (Torbot Group, Inc., Cranston, RI)</li> </ul>	<ul style="list-style-type: none"> <li>• Bonding agents, come as liquid with applicator or spray</li> <li>• Increase adhesion of pouch, wafer, or tape to skin</li> <li>• Should not be used with neonates, premature infants and cautiously with infants</li> </ul>	<ul style="list-style-type: none"> <li>• Improve pouch wear- time</li> <li>• Apply as thinly as possible</li> <li>• Allow liquid to dry completely prior to pouch application to prevent chemical dermatitis</li> <li>• Products vary widely. Follow manufacturer instructions specific for each product</li> </ul>	<ul style="list-style-type: none"> <li>• May contain latex</li> <li>• May contain alcohol and substances with risk of toxicity and future sensitization</li> <li>• Contraindicated on infants and patients with fragile skin – may cause epidermal stripping with adhesive removal</li> <li>• Benzoin, although an adhesive enhancer, is not recommended for use under ostomy appliances</li> </ul>

**Table 3. Accessory Ostomy Products**

<b>Ostomy Accessory</b>	<b>Examples*</b>	<b>Description</b>	<b>Benefits/Tips</b>	<b>Precautions</b>
Adhesive remover  Sometimes called: Solvents	Medi-Sol Adhesive Remover (Orange-Sol Medical Products, Inc., Gilbert, AZ)	<ul style="list-style-type: none"> <li>• Dissolves adhesives</li> <li>• Aid in removal of tape, skin adhesives and residue from skin barrier products</li> </ul>	<ul style="list-style-type: none"> <li>• Minimizes skin trauma/pain with tape and pouch removal</li> <li>• Some are not water- soluble and must be removed with soap and water immediately following use</li> </ul>	<ul style="list-style-type: none"> <li>• Absorbed through epidermal necrolysis</li> <li>• Contains alcohol. Topical alcohol has documented topical and systemic effects in infants (skin blistering, burns, necrosis, elevated alcohol levels, death) skin</li> <li>• May contain petroleum distillates or hydrocarbon derivatives which have potential and proven toxicities</li> <li>• Use is associated with development of toxic epidermal necrolysis in all age groups</li> <li>• Limit use in infants to situations in which the epidermis would otherwise be damaged with adhesive removal and removal cannot be postponed</li> </ul>

**Table 3. Accessory Ostomy Products**

<b>Ostomy Accessory</b>	<b>Examples*</b>	<b>Description</b>	<b>Benefits/Tips</b>	<b>Precautions</b>
Barrier supplements/strips  Sometimes called: • Caulking • Putty • Moldable barrier	• Adapt Barrier Rings and Strips (Hollister, Inc.) o Barrier #54 (Nu-Hope Laboratories, Inc.) o Eakin Cohesive Seal (ConvaTec, Princeton, NJ) o Skin Barrier Caulking Strips (Nu-Hope Laboratories, Inc.) o Stomahesive Strips Moldable Adhesive (ConvaTec) o Strip Paste (Coloplast Corporation, Minneapolis, MN)	• Pectin-based solid skin barrier material containing adhesives and softeners • Soft and moldable when warmed • Added beneath wafer to decrease barrier breakdown by effluent or to level the pouching surface	• May improve pouch wear-time on stoma with large-volume, liquid or caustic effluent. Because these products do not contain alcohol, their use is not irritating to denuded peristomal tissue • Pieces of barrier can be placed in skin folds/creases to level the pouching surface and improve pouch seal • Can be placed circumferentially or unilaterally around stoma. May be shaped to provide mild convexity when needed • Easier to work with when pre-warmed	• Warming under radiant warmer may overheat barrier and damage peristomal skin • Adds to the cost of the pouching system
Belt (ostomy)	• Manufacturers each have belts that fit their own appliance. Several manufacturers make child-sized belt: Marlen Manufacturing & Development Co., Bedford, OH Hollister, Inc. Nu-Hope Laboratories, Inc. (also has infant sizes)	• Used to support pouch adhesion when pouch wear-time is inadequate • Provides pouch support at 3 o'clock and 9 o'clock position	• Useful with active child, obese or soft abdomen • Provides support for convex pouching system • Attachment loops for belt are built into two-piece and some one-piece pouches • Belt/attachment loops may not be interchangeable between manufacturers • Some one-piece pouches require addition of belt adaptor or support shield to anchor belt to pouch • Are washable/reusable	Tend to migrate up to waistline. May exert upward tension on pouch and dislodge if stoma positioned low on abdomen

**Table 3. Accessory Ostomy Products**

<b>Ostomy Accessory</b>	<b>Examples*</b>	<b>Description</b>	<b>Benefits/Tips</b>	<b>Precautions</b>
Binder (ostomy or kemia binder)	Nu-Form Ostomy Support Belts (Nu-Hope Laboratories, Inc.) – various sizes, including sizes suitable for children	<ul style="list-style-type: none"> <li>• Wide, elastic, wrap-around support garment with opening for pouch</li> <li>• Velcro fastener</li> <li>• Provides circumferential stabilization of pouch when adhesion is inadequate. Supports parastomal hernia so that pouch adhesion is maintained</li> </ul>	<ul style="list-style-type: none"> <li>• Useful for active child, small child that pulls off pouch, obese or soft abdomen, convex pouching system and support of parastomal hernia</li> <li>• Minimum tendency to migrate upward due to wide base of support</li> <li>• Comes in variety of widths and lengths, including pediatric sizes</li> <li>• Custom ordering available for unusually sited stomas, multiple stomas or hard-to-fit patients</li> <li>• Can be ordered with prolapse overbelt to maintain reduction of prolapsing stoma or to provide stoma protection during sports</li> </ul>	<ul style="list-style-type: none"> <li>• Can be overly warm to wear during the summer</li> <li>• The use of elastic stretch wraps or self-adhesive stretch wraps is discouraged since they may restrict respirations; use of a binder is preferable</li> </ul>

**Table 3. Accessory Ostomy Products**

<b>Ostomy Accessory</b>	<b>Examples*</b>	<b>Description</b>	<b>Benefits/Tips</b>	<b>Precautions</b>
Convexity	<ul style="list-style-type: none"> <li>• Integrated into barrier: Coloplast Corp. ConvaTec Hollister, Inc. Marlen Manufacturing &amp; Development Co. Nu-Hope Laboratories, Inc. (includes oval, child-sized)</li> <li>• Add-on products to create convexity: Adapt Convex Barrier Rings (3 sizes) (Hollister, Inc.) Convex insert (ConvaTec) Convex insert for infant pouch (Nu-Hope Laboratories, Inc.) Convex insert (regular, medium and deep convexity) (Torbot Group, Inc.)</li> <li>• Custom-made convexity: Nu-Hope Laboratories, Inc. Torbot Group, Inc.</li> </ul>	<ul style="list-style-type: none"> <li>• Mechanically reshapes peristomal area to maximize stomal protrusion</li> <li>• Commercially integrated on some pouches as outward curve of the wafer, with greatest depth of protrusion around the stoma opening</li> <li>• Can be created with ostomy accessories including: 1. Moldable barrier supplement, including some specifically designed to create convexity 2. Molded hard plastic insert which fits into the flange of some two-piece pouches</li> </ul>	<ul style="list-style-type: none"> <li>• Increases stoma protrusion with flush or retracted stoma</li> <li>• Occasionally useful with loop stoma having mucous fistula at skin level</li> <li>• Useful with soft or obese abdomen</li> <li>• Commercially manufactured convex pouches come as one- and two-piece pouches with various depths (shallow, moderate and deep) and various degrees of flexibility</li> </ul>	<ul style="list-style-type: none"> <li>• Allow healing of mucocutaneous suture line prior to use (to prevent suture line separation)</li> <li>• Continuous use may cause pressure ulceration of peristomal skin</li> <li>• Use with caution in the presence of a parastomal hernia</li> <li>• Avoid use with liver disease/caput medusae, as pressure can cause varices to bleed (Pediatric Subcommittee of the Wound, Ostomy and Continence Nurses Society, 2010).</li> <li>• Avoid use with prolapsing stoma (can constrict stoma leading to laceration/ ischemia)</li> <li>• If using molded insert, must clear stoma by one-eighth inch internal diameter</li> </ul>



**Table 3. Accessory Ostomy Products**

<b>Ostomy Accessory</b>	<b>Examples*</b>	<b>Description</b>	<b>Benefits/Tips</b>	<b>Precautions</b>
Deodorant (for use inside ostomy pouch)	<ul style="list-style-type: none"> <li>• Adapt Lubricating Deodorant (Hollister, Inc.)</li> <li>• m9 (Hollister, Inc.)</li> <li>• O.A.D. Concentrated Liquid Ostomy Appliance Deodorant (Coloplast Corp.)</li> <li>• Osto-Pure Deodorizer (pre-measured packets) (Nu-Hope Laboratories, Inc.)</li> <li>• Odour-Guard (Marlen Manufacturing &amp; Development Co.)</li> </ul>	Liquid or powder deodorant for use inside ostomy pouches, neutralizes odor of stool and urine	<ul style="list-style-type: none"> <li>• Add to pouch after each emptying</li> <li>• Deodorant combined with lubricant aids emptying stool from pouch</li> </ul>	<ul style="list-style-type: none"> <li>• Adds to cost of ostomy care</li> <li>• As with all products, use with caution in infants</li> </ul>
Gas filter/vent	<ul style="list-style-type: none"> <li>• FiltrOdor (Coloplast Corp.)</li> <li>• Osto-EZ Vent Ostomy Pouch Venting System (KEM Enterprises, Inc., Grand Rapids, MI)</li> </ul>	<ul style="list-style-type: none"> <li>• Device added to pouch to release gas without opening bottom drain</li> <li>• May be commercially integrated into pouch or added as an accessory prior to pouch application</li> </ul>	<ul style="list-style-type: none"> <li>• Used to prevent accumulation of large amounts of gas which may prematurely dislodge pouch</li> <li>• Commercially incorporated gas filters contain charcoal to neutralize odor as gas escapes from pouch continuously</li> <li>• Add-on gas filters come as:               <ol style="list-style-type: none"> <li>1. "Stick-on" adhesive charcoal filter (pierce filter and pouch with needle to open vent) – re-leases gas slowly but continuously</li> <li>2. Stick-on plug-type vent – gas released by opening vent plug as needed</li> </ol> </li> <li>• Add on gas filters should be placed high on pouch and added prior to applying pouch to patient</li> <li>• Stick-on gas filters may need to be re- pierced daily</li> </ul>	<ul style="list-style-type: none"> <li>• Commercially incorporated gas filter becomes ineffective when wet or clogged with liquid stool</li> <li>• Cover commercial filters when bathing or swimming to keep filter dry (adhesive filter covers included with pouches)</li> <li>• When piercing stick-on style filters, avoid piercing through back of pouch</li> <li>• Piercing pouch with needle to release gas without having add-on gas filter in place will result in leakage of stool and odor</li> </ul>

**Table 3. Accessory Ostomy Products**

<b>Ostomy Accessory</b>	<b>Examples*</b>	<b>Description</b>	<b>Benefits/Tips</b>	<b>Precautions</b>
Gel crystals/granules	<ul style="list-style-type: none"> <li>• Ile-Sorb Absorbent Gel Packets (Cymed Ostomy Co., Berkeley, CA)</li> <li>• NuSorb Absorption Granules (Nu-Hope Laboratories, Inc.)</li> <li>• ParSORB Absorbent Gel Packets/Absorbent Crystals (The Parthenon Co., Inc., Salt Lake City, UT)</li> </ul>	<ul style="list-style-type: none"> <li>• Crystals added to pouch, absorb several times their weight in liquid</li> <li>• Comes as loose crystals/granules or pre-measured, dis- solvable packets</li> <li>• Thickens liquid stool</li> </ul>	<ul style="list-style-type: none"> <li>• Improves wear-time when wafer is being prematurely degraded by liquid effluent</li> <li>• Reduces sloshing of effluent in pouch</li> <li>• Bits of disposable diaper lining containing absorbent gel materials can be placed in the pouch, in lieu of gel crystals, to absorb excess liquid from effluent</li> </ul>	Fecal output must be weighed, as volume will be altered by presence of gel
Liquid skin barrier  Sometimes called: <ul style="list-style-type: none"> <li>• Skin sealant</li> <li>• Skin barrierwipe</li> <li>• Skin prep</li> </ul>	<ul style="list-style-type: none"> <li>• All Kare Protective Barrier Wipes (Con-vaTec)</li> <li>• Cavilon No-Sting Skin Barrier Film (alcohol- free, non-water soluble) (3M Health Care, St. Paul, MN)</li> <li>• No-Sting Skin Prep (alcohol-free, water soluble) (Smith &amp; Nephew, Inc.)</li> <li>• Skin Gel Protective Dressing (Hollister, Inc.)</li> <li>• Skin Prep Skin Barrier Wipes (Smith &amp; Nephew, Inc.)</li> </ul>	<ul style="list-style-type: none"> <li>• Provide a clear, protective film on the skin</li> <li>• Come as wipes or spray, liquid or gel</li> <li>• Contain a plasticizing agent</li> <li>• May or may not be water-soluble, depending on brand</li> <li>• May contain isopropyl alcohol</li> </ul>	<ul style="list-style-type: none"> <li>• Protects skin from friction damage/epi-dermal stripping due to frequent adhesive removal</li> <li>• Non-water soluble types protect skin from exposure to moisture/effluent</li> <li>• Air dry after ap- plication, allowing chemicals to evaporate prior to covering</li> </ul>	<ul style="list-style-type: none"> <li>• May reduce pouch adherence by pre-venting the hydrocolloid from absorbing moisture</li> <li>• Occasionally improves pouch adhesion, in the presence of high humidity or excess perspiration</li> <li>• Alcohol, in alcohol-containing liquid br rier, can be absorbed through the skin</li> <li>• May cause chemical dermatitis beneath pouch</li> <li>• Application of alcohol-containing liquid barrier to denuded skin will cause burning sensation</li> <li>• Precautions in infants: Use only alcohol- free skin sealant Limited safety data on use with pre- term infants or term infants &lt; 30 days of age</li> </ul>

**Table 3. Accessory Ostomy Products**

<b>Ostomy Accessory</b>	<b>Examples*</b>	<b>Description</b>	<b>Benefits/Tips</b>	<b>Precautions</b>
<p>Moisture barrier skin ointment/paste</p> <p>Sometimes called:</p> <ul style="list-style-type: none"> <li>• Butt paste</li> <li>• Diaper rash ointment</li> <li>• Skin barrier ointment/ paste</li> </ul> <p><i>These are not the same products as ostomy skin barrier pastes used for leveling peristomal skin surfaces</i></p>	<ul style="list-style-type: none"> <li>• Calmoseptine Ointment (Calmoseptine, Inc., Huntington Beach, CA)</li> <li>• Critic Aid Anorectal Skin Paste (Coloplast Corp.)</li> <li>• iLEX Skin Protectant Paste (Medcon Biolab Technologies, Inc., Grafton, MA)</li> <li>• Sensi-Care Protective Barrier (ConvaTec)</li> <li>• Critic AID Clear Barrier cream (Coloplast, Corp.)</li> <li>• Aleo Vesta Protective Barrier cream (ConvaTec)</li> </ul>	<ul style="list-style-type: none"> <li>• Occlusive ointments/ pastes for use to protect perianal skin from effluent and to heal denuded peri- anal skin</li> <li>• Have the ability to adhere to denuded skin when common over-the-counter petrolatum or zinc-oxide preparations do not</li> </ul>	<ul style="list-style-type: none"> <li>• Useful following stoma takedown when incontinence associated dermatitis is common and can be severe</li> <li>• Can be applied over denuded, weeping skin</li> <li>• Paste tends to adhere to diaper. Application of petrolatum or a dusting of skin barrier (ostomy) powder over the paste layer helps prevent paste from adhering to the diaper and thereby being removed from the skin</li> <li>• When cleaning stool from skin, remove only visible soiling. Do not remove all paste. Re-apply paste and petrolatum as needed.</li> <li>• Can be used to protect peristomal skin if using the non-pouching option for stoma management (Pediatric Subcommittee of the Wound, Ostomy and Continence Nurses Society, 2010).</li> </ul>	<ul style="list-style-type: none"> <li>• Does not need to be removed from skin on a regular basis</li> <li>• Should not be scrubbed off of skin or further damage to compromised skin may occur</li> <li>• If visualization of skin is desired, cotton balls or a soft cloth saturated with mineral oil or baby oil will remove paste automatically</li> </ul>

**Table 3. Accessory Ostomy Products**

<b>Ostomy Accessory</b>	<b>Examples*</b>	<b>Description</b>	<b>Benefits/Tips</b>	<b>Precautions</b>
<p>Pouch closure</p> <p>Sometimes called:</p> <ul style="list-style-type: none"> <li>• Tail closure</li> <li>• Tail clamp</li> <li>• Tail clip</li> </ul>	<ul style="list-style-type: none"> <li>• Manufacturers each make their own version</li> <li>• Clip or wire-style closures</li> <li>• Commercially incorporated interlocking non adhesive closures include: Assura® Easi Close™ (Coloplast Corp.) InvisiClose™ Clip-less Tail Closure (ConvaTec) Lock'n Roll Closure System™ (Hollister, Inc.)</li> </ul>	<p>Device which closes an open-ended, drainable fecal pouch</p>	<ul style="list-style-type: none"> <li>• Attach one-half inch from distal pouch opening</li> <li>• Three options include: 1. Disposable “soft” flexible wire closure (“bread tie”)—generally used on pediatric pouches; low likelihood of damaging fragile skin 2. Rubber band can be used as a pouch closure—wrap around open end of pouch which has been folded up from bottom and accordion-pleated; useful if child likely to remove tail closure 3. Non-disposable, “hard” plastic closure—useful on adult-size pouches including those used on infant with edematous or prolapsed stoma, high-volume output</li> </ul>	<ul style="list-style-type: none"> <li>• Flexible closure has adhesive backing with which to attach to pouch. Provided one per pouch—not reusable</li> <li>• Flexible closure may leak if end of pouch not wrapped tightly around wire at least three times</li> <li>• Fold ends of disposable wire away from skin to avoid damage</li> <li>• Only need to fold pouch tail over inside edge of non-disposable clamp one time. Tug on pouch-end to check that closure is correctly fastened</li> <li>• Only one non-disposable clamp per box of pouches—must be reused</li> <li>• Plastic may traumatize fragile skin or cause pressure ulcer if patient lays on clamp for extended time</li> </ul>

**Table 3. Accessory Ostomy Products**

<b>Ostomy Accessory</b>	<b>Examples*</b>	<b>Description</b>	<b>Benefits/Tips</b>	<b>Precautions</b>
<p>Skin barrier pasta (ostomy paste)</p> <p><i>This is NOT the same product as moisture barrier skin ointments used for diaper dermatitis</i></p>	<ul style="list-style-type: none"> <li>• Adapt Paste (Hollister, Inc.)</li> <li>• Ostomy Paste (Coloplast Corp.)</li> <li>• Stomahesive Paste (ConvaTec)</li> </ul>	<ul style="list-style-type: none"> <li>• Hydrocolloid-based paste in a tube</li> <li>• Applied in skin depressions around stoma to create a level pouching surface, prevent tunneling of effluent under pouch, improve pouch adhesion</li> <li>• May contain alcohol as preservative</li> </ul>	<ul style="list-style-type: none"> <li>• Can be applied circumferentially around stoma as a thin ring or as individual beads of paste to level peri- stomal skin creases or depressions</li> <li>• Apply minimum volume needed to maintain pouch seal</li> <li>• Can be squeezed into barrel of syringe and applied in small amounts—particularly useful with infants and small children, where volume of paste should be limited</li> <li>• Application to wafer (rather than to skin) 1 minute prior to pouch application allows some evaporation of alcohol</li> <li>• Moistened cotton-tip applicator, or gloved hand with finger tip moistened with water, can be used to shape paste around stoma</li> </ul>	<ul style="list-style-type: none"> <li>• NOT to be used as a “glue” to attach pouch to abdomen</li> <li>• NEVER apply to the entire barrier</li> <li>• Will cause burning sensation if used on denuded skin</li> <li>• Use on infants is <b>STRONGLY</b> discouraged due to aggressive adhesion, alcohol content</li> <li>• Expected wear-time should be &gt; 24 hours to minimize epidermal irritation/stripping with removal</li> <li>• NEVER use as a skin barrier paste around stoma when employing a non-pouching approach or on but- tocks for treatment of diaper dermatitis</li> </ul>

**Table 3. Accessory Ostomy Products**

<b>Ostomy Accessory</b>	<b>Examples*</b>	<b>Description</b>	<b>Benefits/Tips</b>	<b>Precautions</b>
Skin barrier powder (ostomy powder)	<ul style="list-style-type: none"> <li>• Premium Powder (Hollister, Inc.)</li> <li>• Stomashesive Powder (ConvaTec)</li> </ul>	<ul style="list-style-type: none"> <li>• Hydrocolloid-based powder</li> <li>• Absorbs fluid when dusted onto denuded skin, improving pouch adhesion</li> </ul>	<ul style="list-style-type: none"> <li>• Apply only to denuded skin</li> <li>• Apply minimal amount required to control excess moisture on pouching surface and gently dust off excess powder</li> <li>• Pouch adhesion may be improved by “sealing” powder—blot powder with damp finger or alcohol-free liquid barrier wipe/ spray. Allow to dry before pouch application</li> <li>• In the presence of excess moisture on denuded peristomal skin, re-application of powder and skin sealant in layers may be required to control moisture</li> <li>• Can be used on severe diaper dermatitis to improve adhesion of moisture barrier skin ointment</li> </ul>	<ul style="list-style-type: none"> <li>• Powder may aerosolize when squeezed from a bottle. Use precautions with infants to prevent inhalation (powder inhalation has been documented to cause respiratory distress/ death in infants: Powder may aerosolize when squeezed from bottle direct stream away from infant’s face Enlarge bottle opening to prevent aerosolizing powder when bottle is squeezed Shield infant’s face Apply smallest amount that will manage exudate Brush, rather than blow, to remove excess powder</li> </ul>



**Table 3. Accessory Ostomy Products**

<b>Ostomy Accessory</b>	<b>Examples*</b>	<b>Description</b>	<b>Benefits/Tips</b>	<b>Precautions</b>
Leg bags or Nighttime urine collectors	<ul style="list-style-type: none"> <li>• Leg bag: Curity Urine Leg Bag (The Kendall Co., Mansfield, MA)</li> <li>Freedom Disposable Leg Bags (latex-free) (Men- tor Corp., Santa Barbara, CA)</li> <li>Latex-Free Urinary Leg Bag Kit (Hollister, Inc.)</li> <li>Security + Leg Bag (Coloplast Corp.)</li> <li>• Nighttime urine collector: Bedside Drainage Collection System (Hollister, Inc.)</li> <li>Night Drainage Container Set (ConvaTec)</li> <li>Night Drainage Kit (Marlen Manufacturing &amp; Development Co.)</li> <li>Urine Collection Bottle (Nu-Hope Laboratories, Inc.)</li> </ul>	<ul style="list-style-type: none"> <li>• Collection device, extends the interval for emptying pouch</li> <li>• Particularly useful for nighttime drainage, to avoid having to empty pouch during the night</li> <li>• Useful with high-output jejunostomy or ileostomy</li> </ul>	<ul style="list-style-type: none"> <li>• Comes in two styles:               <ol style="list-style-type: none"> <li>1. Small collection bag with tap/drain- age spout, straps to lower leg ("leg bag"). Connects to urinary pouch with drainage tubing. Useful when ambulatory</li> <li>2. Large, stand-alone collection container or bag which hangs at bedside. Attaches to urinary or high-output pouch with long drainage tubing. Used during sleep or extended bed rest (bedtime drainage or night-time drainage container)</li> </ol> </li> <li>• Leg bag may be strapped to lower leg, thigh, or occasionally around abdomen of crawling infant</li> <li>• Leg bag may be strapped to lower leg, thigh, or occasionally around abdomen of crawling infant</li> <li>• Leg bags may be useful as nighttime urine collector in small infants when pouch capacity is appropriate</li> <li>• Nighttime collection container can be placed inside a clean wastebasket to prevent overturning</li> <li>• To prevent extension tubing connecting pouch to urine collection container from kinking as child turns during sleep:               <ol style="list-style-type: none"> <li>a) Secure tubing to leg with tube-type article of clothing (open-toed tube sock or cut-off section of tights)</li> <li>b) Have tubing exit from foot of bed rather than side</li> </ol> </li> </ul>	<ul style="list-style-type: none"> <li>• Tubing may become tangled during sleep, obstructing urine drainage</li> <li>• Collection container must be in a dependent position to allow drainage away from stoma</li> </ul>


**Table 3. Accessory Ostomy Products**

<b>Ostomy Accessory</b>	<b>Examples*</b>	<b>Description</b>	<b>Benefits/Tips</b>	<b>Precautions</b>
Zinc-based waterproof (pink) tape	<ul style="list-style-type: none"> <li>• Hy-Tape the Original Pink Tape (latex-free) (Hy-Tape International, Patterson, NY)</li> <li>• Pink Tape (Nu-Hope Laboratories, Inc.)</li> </ul>	<ul style="list-style-type: none"> <li>• Waterproof tape with gentle adhesive</li> <li>• Useful for water- proofing pouch wafer in areas exposed to moisture</li> <li>• Adheres to slightly moist skin</li> </ul>	<ul style="list-style-type: none"> <li>• Reinforcing edge of wafer exposed to urine, wound drainage, fistula output with tape can improve wear-time</li> <li>• Wafer can be “picture-framed” with tape to protect against water expo- sure during swimming, bathing</li> </ul>	Use of tape on infant skin, particularly premature infants, should be minimized due to the risk of skin damage

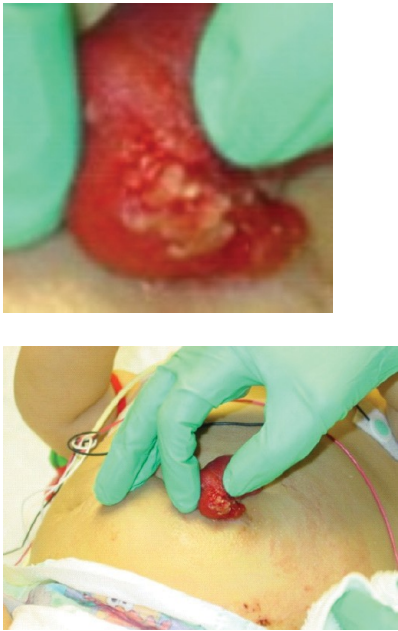
### **Disclaimer**

Brand names/manufacturers are representative examples of ostomy accessories. This list is not inclusive of all products available in the category, nor is it intended to be a recommendation of listed products.

**Table 4. Trouble-Shooting Section**

Complication	Definition	Treatment
<p>Caput Medusae</p>	<p>This condition is caused by dilation of cutaneous peristomal veins (peristomal varices) coursing away from the umbilicus or stoma. The peristomal skin appears bluish/purple and is thin and fragile. Children with liver disease are at risk for developing the varices and stoma bleeding.</p>	<p>Minor bleeding may stop spontaneously but occasionally topical hemostatic agents such as silver nitrate, calcium alginate dressing or absorbable hemostat with direct pressure may help to stop any small spontaneous bleeds. Severe bleeding may require suturing or surgical intervention.</p> <p>Less frequent pouch changes, gentle stoma/peristomal care and removal technique, use flexible one-piece pouches or two-piece flexible adhesive coupling pouches.</p> <p>Protect the surrounding skin with a skin barrier that does not sting the skin under the appliance.</p> <p>Avoid non-essential adhesive products since rubbing of skin to remove may risk bleeding.</p>
<p>Central Lines and Stomas (Prevention of Contamination with Feces)</p> 	<p>Infants and young children who have central lines and ostomies are at risk for cross-contamination from stool, which can lead to infection. Leakage of ostomy pouch may contaminate central line if line dangles over or near the pouch. If pouch is emptied, leaks or is pulled off, the contents may spread to line area and result in an infection.</p>	<p>Position central line ports away from the stoma or pouch at all times. Schedule routine pouch changes to avoid leakage between pouch changes.</p> <p>Transparent dressing is suggested so site can be easily assessed.</p> <p>Tape central line up over the shoulder away from the pouch and secure with tubular stretch net dressing around the child's chest.</p> <p>When emptying the pouch, position the central line away from the pouch; ports may be wrapped with a cloth or gauze to prevent contamination from stool.</p>


**Table 4. Trouble-Shooting Section**

Complication	Definition	Treatment
<p>Lacerations</p> 	<p>Stoma laceration may develop as a result of pouching technique or due to trauma.</p> <p>Frequently the mucosal injuries are shallow, and, since the stoma does not contain any nerve endings, they do not result in pain for the patient. A laceration is usually a yellow or white linear discoloration in the stoma mucosa. The child often reports the presence of fresh blood in the pouch with no clear reason for the bleeding.</p>	<p>Identify and eliminate the causative factor. Topical hemostatic agents such as silver nitrate or the application of an alginate dressing may be required along with direct pressure.</p> <p>Assess pouch fit and pouching system. Pouch may be sized too small or a protruding (prolapsed) stoma may have gotten pinched or rubbed against the rim of a flange or convex insert. The stoma opening for the pouch needs to be resized periodically as the child grows, since the stoma also grows. Too small of an opening may result in a stoma laceration.</p> <p>Peristaltic movements of the bowel may result in a larger bowel, so the opening must be cut accordingly.</p> <p>An older adolescent needs to use caution if shaving abdominal hair around stoma and shave away from the stoma. The use of an electric razor should be emphasized.</p> <p>Assess tightness of clothing over stoma potentially attributing to laceration.</p> <p>If the cause of stoma laceration is sports related, look into protective devices to protect the stoma during contact sports.</p>

**Table 4. Trouble-Shooting Section**


Complication	Definition	Treatment
Leak Management/High Output Stoma	This problem is commonly due to an incorrect fitting appliance, the need for convexity for a flush or retracted stoma or weight changes in the patient. The stoma may be located in an abdominal crease or may have excessive small bowel output (high ileum, jejunum, malabsorption).	<p><u>Leak Management:</u> Assess pouch fit, correct flange size or add convexity if necessary. Schedule routine changes to help avoid leak- age between pouch changes. Protect peristomal skin with skin barriers more durable and resistant to meltdown (e.g., extended wear barriers). Use skin barrier (ostomy) paste or barrier supplements/strips for crevices and cracks to create a level pouching surface. The use of a stoma belt with complicated stomas may help to raise stoma enough to drain well.</p> <p>Assess clothing choices: infants and toddlers – one-piece undershirts prevent them from playing with the appliance. For adolescents, assess where waistline of pants fits to help prevent clothes from dislodging appliance.</p> <p><u>High Output Stoma:</u> If high output, apply a high output appliance or urostomy pouch connected to a urine collection bag/container.</p> <p>Larger capacity pouch may work better, empty frequently, place absorbent gel crystals/granules into pouch to absorb fluid and turn liquid to gel (will affect measurement of output for I&amp;O) or place cotton balls into pouch.</p> <p>Assess the patient’s dietary intake and limit foods known to increase stool output. The patient may also consult physician for medications to slow the GI tract.</p>

**Table 4. Trouble-Shooting Section**

Complication	Definition	Treatment
<p>Mucocutaneous Separation</p> 	<p>This is an early postoperative complication when the stoma separates at the suture line from the abdominal skin surface. The separation can be partial or circumferential, superficial or deep and must then heal like a scar. This condition can occur in children with compromised healing, when there is excessive tension at the stoma suture line, when the patient is malnourished, receiving steroid therapy or is a diabetic. The separation can lead to total retraction, as well as, infection with symptoms including pain, burning and purulent drainage.</p>	<p>Keep feces and urine away from the defect with saline irrigation and packing.</p> <p>Gently fill the defect with an absorptive dressing, such as hydrofiber or calcium alginate or pectin powder and place a transparent film dressing over the wound. Place pouch on top of transparent film.</p> <p>If drainage from the separation interferes with the pouch adherence, the defect may be covered with skin closure strips (e.g., Steri-strips®, 3M Healthcare, St. Paul, MN) or a hydrocolloid dressing to create a pouching surface. Refit pouch so barrier covers separation.</p> <p>Surgical intervention may be necessary if peritoneal contamination with stool is a potential problem.</p>




**Table 4. Trouble-Shooting Section**

Complication	Definition	Treatment
<p data-bbox="87 300 293 327">Multiple Stomas</p> 	<p data-bbox="576 300 1047 630">It is common for premature babies who have had a bowel resection to have one or more stomas. The stomas are very small and often flush with the skin. The child may experience abdominal distension, the stomas may become dark with questionable viability and the outer layer of these stomas may slough off.</p> <p data-bbox="576 667 1047 798">Children with imperforate anus may also have a double-barrel descending colostomy, which are usually very close together.</p>	<p data-bbox="1079 300 1537 766">Stomas in close proximity can generally be pouched within the same appliance. Select a skin barrier with enough cutting surface to pouch both stomas together. The exception is patients with imperforate anus and a double barrel stoma. Ideally, the mucous fistula should not be pouched with the functioning stoma to prevent crossover of stool to the distal limb of the bowel. However, this is not always practical or possible if the stomas are very close.</p> <p data-bbox="1079 804 1537 1029">Mucous fistula in an infant tends to produce large amounts of mucus causing the adjacent skin barrier wafer to lift up. Using saddle-bagging technique to pouch both the active stoma and mucus fistula can enhance wear time.</p> <p data-bbox="1079 1066 1537 1438">May need to picture frame edges of pouch (e.g., with strips of hydrocolloid dressing, transparent film dressing, zinc-based waterproof tape) to protect the wafer from adjacent moisture or petrolatum from the dressing over mucous fistula. The use of moldable strip paste between the stomas adds more durability and protection to the skin bridge area.</p> <p data-bbox="1079 1476 1537 1795">Create a pattern with two openings to adequately protect the skin bridge between the stomas. If a starter hole is present on the pouch wafer, it can be covered with a piece of barrier or a hydrocolloid placed from the inside of the pouch rather than underneath to avoid leakage caused by the patching.</p>

**Table 4. Trouble-Shooting Section**

Complication	Definition	Treatment
Obstruction	<p>Food blockage is primarily a concern for children with ileostomies and is caused by mechanical obstruction in the small bowel from high residue/high fiber foods that are not chewed thoroughly or from not drinking enough fluids.</p> <p><u>Partial Obstruction Symptoms:</u></p> <ul style="list-style-type: none"> <li>• Decreased output that may be liquid</li> <li>• Foul-smelling stool</li> <li>• Abdominal cramping</li> <li>• High-pitched or hypoactive bowel sounds</li> <li>• Stoma swelling</li> </ul> <p>Stoma retraction may also occur due to fluid pooling proximal to the obstruction in the proximal bowel lumen under the skin but is less common. These symptoms may progress to the complete absence of stoma output.</p> <p><u>Complete Obstruction Symptoms:</u></p> <ul style="list-style-type: none"> <li>• Abdominal distension</li> <li>• Abdominal pain</li> <li>• Nausea</li> <li>• Vomiting</li> </ul> <p>Lack of output of urinary stoma can be indicative of obstruction, infection or dehydration.</p>	<p><u>Teach preventative measures:</u></p> <ul style="list-style-type: none"> <li>• Limited intake of high-fiber/high residue foods.</li> <li>• Thorough chewing of food intermixed with increased fluid intake.</li> <li>• Teach signs and symptoms of partial or complete obstruction.</li> <li>• Instruct caregivers to offer smaller more frequent meals.</li> <li>• Avoid high-fiber/high residue foods for six to eight weeks after ostomy surgery.</li> <li>• Introduce foods one at a time slowly and monitor the effects on output.</li> </ul> <p><u>Interventions:</u></p> <ul style="list-style-type: none"> <li>• Warm bath, remove pouch or replace with larger aperture to accommodate stoma swelling, pull knees up to abdomen and lying on the side, peristomal massage.</li> <li>• Increasing fluid intake, if not vomiting, may relieve the obstruction. Warm fluids by mouth are better than cold fluids, since warm fluids will help to stimulate peristalsis.</li> <li>• Notify physician if blockage doesn't pass or symptoms progressively worsen. Seek medical care immediately if symptoms of complete obstruction occur.</li> <li>• Warm fluids will help to stimulate peristalsis.</li> <li>• If the child begins to vomit, notify physicians. Children with ileostomies are more prone to dehydration.</li> </ul>

**Table 4. Trouble-Shooting Section**

Complication	Definition	Treatment
<p>Parastomal Hernia</p> 	<p>This condition is caused by dilation of cutaneous peristomal veins (peristomal varices) coursing away from the umbilicus or stoma. The peristomal skin appears bluish/purple and is thin and fragile. Children with liver disease are at risk for developing the varices and stoma bleeding.</p>	<p>Assess fit of pouch, may need to change system.</p> <p>One-piece pouching system may be more flexible but a two-piece pouch with a floating flange or adhesive coupling can also be effective. An ostomy belt with a two-piece pouch may be helpful.</p> <p>Support (hernia) binder may help but are not usually used on infants. For infants, stoma belts may offer some support to the peristomal area.</p>

**Table 4. Trouble-Shooting Section**

Complication	Definition	Treatment
<p>Perianal Skin Breakdown After Stoma Closure</p> 	<p>Diaper dermatitis, or perianal skin excoriation, is common following ostomy closure and can quickly lead to severe skin damage and pain. The etiology of perianal skin breakdown in these infants has not been studied, but several etiologies have been proposed:</p> <ul style="list-style-type: none"> <li>• Perianal skin has limited or no exposure to stool until stoma closure, when it is suddenly exposed to caustic fecal enzymes.</li> <li>• Shortened intestinal length from bowel resection can decrease GI transit time and result in malabsorption, producing stool with more fecal enzymes, bile salts and a higher pH than normal infant stool (Lund, 1999).</li> <li>• Surgical insult to the bowel causes inflammation and edema with decreased stool transit time, leading to postoperative diarrhea.</li> <li>• Perioperative antibiotic administration alters normal bowel flora, encouraging bacterial overgrowth and loose stools.</li> <li>• Infants with congenital diseases having a component of intestinal dysmotility (Hirschsprung's disease, anorectal malformations) or abnormal anal sphincter tone (anorectal malformations, exstrophy conditions, myelomeningocele) have frequent, if small, stools. This can lead to excessive skin exposure to stool and perineal irritation.</li> <li>• Intrinsic differences in the chemical composition or bacterial content of stools in these infants is also possible, although no data is available.</li> </ul>	<p>Measures to Prevent Perianal Skin Breakdown:</p> <ul style="list-style-type: none"> <li>• Initiate preventive measures immediately after ostomy closure and before stooling resumes, to prevent skin exposure to caustic stool.</li> <li>• Do not "rub off" the protective barrier. Simply dab off the stool to a clean layer and reapply the barrier.</li> <li>• Wash hands before performing perineal skin care. Caregivers' hands are thought to be the most common environmental source of colonization of neonatal skin and can transmit <i>Candida albicans</i>.</li> <li>• Change diaper promptly when wet or soiled to decrease skin moisture and contact with fecal enzymes.</li> <li>• Wipe stool from skin gently, without scrubbing or excessive cleansing. Pat skin dry, rather than wiping. Use a perineal cleanser to help loosen stool.</li> <li>• Routinely protect perianal skin with a protective skin preparation containing zinc oxide or dimethicone.</li> <li>• Avoid topical products containing isopropyl alcohol, camphor, salicylates, boric acid, baking soda or benzocaine. Substances applied to the perineum are absorbed trans epidermally in greater quantities than on other areas of the body, due to the occlusive nature of diapers, and can be harmful.</li> <li>• Antibacterial ointments are not necessary or helpful for irritant diaper dermatitis, as is not associated with an increased number of bacteria.</li> <li>• Disposable diapers with absorbent gel materials are more absorptive and keep perineal skin drier than those without absorbent gel or cloth diapers.</li> <li>• If infant is breastfed, encourage continuation of breastfeeding. Stools of breastfed infants have less colonization by urease-producing organisms, a lower pH and contain less fecal enzymes.</li> </ul> <p>Measures to Heal Excoriated Perianal Skin:</p> <ul style="list-style-type: none"> <li>• Cleanse perineal skin gently with warm water and a soft cloth or cotton balls and pat dry.</li> <li>• A squirt bottle filled with warm water can be used to rinse stool and urine if cleansing with a cloth becomes too painful. Water should be changed with every perineal cleansing to avoid bacterial proliferation in standing water.</li> <li>• Warm sitz baths can be soothing to irritated or excoriated skin and can assist in cleansing skin which may be painful to touch.</li> </ul>

**Table 4. Trouble-Shooting Section**

Complication	Definition	Treatment
		<ul style="list-style-type: none"> <li>• Feces dried onto the skin or barrier ointment can be removed without trauma to the skin by using cotton balls and mineral oil.</li> <li>• If cleansing the diaper area with soap, use a mild, pH-neutral soap. Alkaline soaps disrupt the acid mantle of the skin for extended periods and can change the cutaneous flora.</li> <li>• Avoid use of commercial infant wipes. Some contain alcohol, which can be painful to irritated skin. Most commercial wipes contain fragrances that could topically sensitize. Commercial infant wipes have been shown to change the skin pH.</li> <li>• For acute or exudative dermatitis, wet compresses using normal saline or Burow's solution (or Domeboro solution) (one packet to 16 oz – one quart of water) can be applied prior to application of barrier ointment to soothe painful skin. No data is available supporting the use of Burow's solution on preterm infants.</li> <li>• Protect perianal skin with zinc oxide- based barrier cream, ointment or paste. Zinc oxide provides a water impermeable barrier and prevents irritants from contacting the skin. It also acts as a drying agent to over- hydrated or exudating skin.</li> <li>• When removing stool from skin, clean only visible contamination, leaving residual barrier ointment. Barrier ointment does not need to be removed. Frequent or vigorous removal of barrier ointment can further traumatize damaged skin.</li> <li>• If excoriated (denuded) skin prevents barrier ointment from adhering, change to a commercial barrier paste manufactured to adhere to excoriated skin (many are pectin or carboxmethylcellulose-based) covered with a layer of petrolatum or zinc oxide ointment. Petrolatum layer can be wiped away with stool, leaving pectin-based paste in place. Re-apply barrier ointment and petrolatum, as needed, with each diaper change.</li> <li>• Alternately, lightly dust excoriated skin with skin barrier (ostomy) powder will absorb moisture and provide a tacky surface to which a zinc oxide ointment can then be applied.</li> <li>• Following removal of barrier ointment from perineal skin or bathing, air- drying perineal skin can help reverse over-hydration of the skin resulting from exposure to urine and temporarily remove friction caused by the diaper.</li> </ul>

**Table 4. Trouble-Shooting Section**


Complication	Definition	Treatment
		<ul style="list-style-type: none"> <li>A compromised skin barrier due to diaper dermatitis may lead to secondary infection with bacteria or fungus, commonly <i>Candida albicans</i>, <i>Staphylococcus aureus</i> or <i>Streptococcus</i> species. Identify and obtain treatment orders for secondary perianal infections. Although resident flora of the intestine or skin, these infections must be treated with appropriate topical or oral antibiotics. When applying an antifungal cream, always put a barrier cream over it since it has no protection property. The antifungal is applied two to three times a day while the protective barrier should be applied as many times as needed, but always over the antifungal cream.</li> </ul>
<p>Peristomal Skin Breakdown</p> <p>a) irritant contact dermatitis</p> <p>b) allergic dermatitis</p> <p>c) folliculitis</p> <p>d) fungal infection</p> <p>*Each subtype will be discussed in detail in the following sections</p>	<p><u>Peristomal Breakdown Types:</u></p> <ul style="list-style-type: none"> <li>Mechanical</li> <li>Chemical</li> <li>Allergic</li> <li>Infectious Means</li> </ul> <p><u>Peristomal Breakdown Causes:</u></p> <ul style="list-style-type: none"> <li>Seepage of stoma effluent under the appliance wafer.</li> <li>Failure to change a leaking pouch promptly and attempts to tape a leaking pouch which traps stool/urine under the barrier.</li> <li>Prolonged wearing of the pouch with barrier meltdown.</li> <li>Skin stripping from adhesives.</li> <li>Trauma due to an ill fitting appliance.</li> <li>Mechanical trauma from harsh removal of the pouch or picking at the skin to remove stoma paste.</li> </ul> <p>This breakdown may lead to involvement of the dermis that is painful, moist and may bleed.</p>	<p>“Push/Pull” removal technique – push down on skin while gently pulling up on pouch/barrier to remove.</p> <p>Warm water to clean peristomal skin; avoid harsh soaps and other chemicals on the skin. May use mild, non-fragranced soap to cleanse skin, but rinse thoroughly with water.</p> <p>Minimize number of accessory products (e.g., liquid skin barrier, adhesives, adhesive removers, tapes), especially if they contain alcohol, which will irritate and burn broken skin - “Less is Best”.</p> <p>(Note: some adhesives contain latex - do NOT use if child has latex allergy or precaution.)</p> <p>Eliminate cause of breakdown, check the fit of pouch and pouching regimen.</p> <p>Apply barrier (ostomy) powder to the skin, seal with non-alcohol based liquid skin barrier, re-pouch with correct size pouch, create new pattern for stoma opening.</p>

**Table 4. Trouble-Shooting Section**


Complication	Definition	Treatment
a.) Irritant contact Dermatitis	<p><u>This is caused from prolonged exposure to irritating substances:</u></p> <ul style="list-style-type: none"> <li>• Urine</li> <li>• Feces</li> <li>• Digestive Enzymes from Ileostomy</li> </ul> <p>The skin appears inflamed, moist and painful.</p> <p>It is commonly caused by skin exposure to stool leakage when there is an incorrectly fitting pouch or with a flush or retracted stoma that may be located in a skin crease.</p>	<p>Properly clean the skin to remove the effluent and digestive enzymes and assess the pouching system.</p> <p>Treat minor skin irritations with stoma powder dusted on and excess brushed off (*caution—do not brush toward an infant’s face), seal with a dab of water or non-alcohol-based skin sealant.</p> <p>Cut appropriate size opening for stoma (1/8-inch larger than stoma). Skin barrier (ostomy) paste contains alcohol and can burn excoriated skin. Substitute alcohol-free barrier supplements/strips for a better pouch fit.</p> <p>The use of a belt can be used to obtain the optimal benefit of the convexity.</p> <p>If stoma is flush or retracted, convexity of the wafer will push the surrounding skin down around the stoma and can improve the fit, pushing the stoma outward into the pouch. Mild convexity can be created with barrier supplements/strips.</p> <p>Deeper convexity can be created with insert rings fitting into the flange of a two-piece system. There are also one- and two-piece pouches with built in convexity (mild, moderate and deep).</p>



**Table 4. Trouble-Shooting Section**

Complication	Definition	Treatment
<p>b.) Allergic Contact Dermatitis</p> 	<p>This condition is suspected when the reddened area corresponds precisely to the area covered by a product.</p> <p>It can develop from exposure to any pouching system or accessory ostomy products and skin appears red, itchy, scaly and inflamed.</p> <p>Once skin sensitivity develops, it may become a chronic problem. Patients with known allergies are more at risk for reactions.</p> <p>This can be caused by the misuse of stoma accessories (i.e., deodorizers, perfumed or medicated wet wipes) or a hypersensitivity to the plastic, appliance or the adhesive.</p>	<p>Remove the offending product.</p> <p>Avoid the use of accessory products unless absolutely necessary. If they are necessary, ensure they are used correctly, i.e., let the skin barrier wipe dry before placing the ostomy wafer.</p> <p>Patch testing may be necessary to determine the allergen, contact the WOC (ET) nurse or Clinical Nurse Specialist for assistance.</p> <p>Consult with a physician for possible topical steroid treatment for severe cases.</p>
<p>c.) Folliculitis</p>	<p>This is an inflammation of the hair follicle, which may be caused by aggressive removal of the ostomy pouch abruptly pulling abdominal hair from the root or by frequent shaving of peristomal hair. A superficial rash may occur and resemble candida, be red and inflamed and may contain purulent drainage. The bacterial infection is often caused by streptococci or staphylococcus aureus. A swab culture of the pustules can be obtained to test for antibiotic sensitivity and treatment.</p>	<p>Evaluate the pouching system and pouch removal technique. Assess technique for removing hair from peristomal skin. Preventative measures include: a) using an electric razor; b) use scissors to clip the hair close or; c) a depilatory followed with thorough cleansing of skin. “Dry shave” using a new razor and protective barrier (ostomy) powder. Rinse off powder and hair with water when finished.</p>



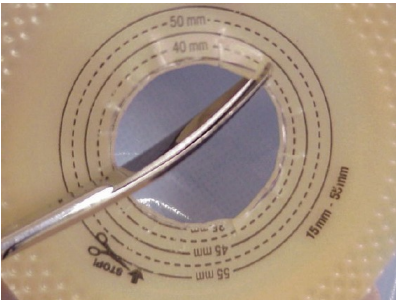
**Table 4. Trouble-Shooting Section**

Complication	Definition	Treatment
<p>d.) Fungal Infection</p> 	<p>A rash can present as diffuse redness around stoma, or pinpoint satellite red bumps on the surrounding skin.</p> <p>The patient often complains of burning or itching around the stoma.</p> <p>Yeast thrives in moist, warm, dark environments. This often occurs with a poor fitting appliance that is leaking, moisture build up after bathing, perspiration on the skin next to a plastic pouch or after a child has been on antibiotics.</p>	<p>Treatment for <i>Candida albicans</i> is with a topical antifungal agent (e.g., miconazole, nystatin, or clotrimazole), which is supplied as a cream or powder. It is best to avoid creams since creams may impair pouch adhesion. Spray forms of antifungal agents do contain alcohol and may sting when applied. Using an antifungal powder, lightly dust powder under pouch wafer area and remove excess, seal with dabs of water or alcohol free skin sealant. Pouch should be changed every 48 hours to retreat skin.</p> <p>Cotton pouch covers, gauze or absorbent powders are helpful in the summer to absorb moisture trapped under pouch material.</p> <p>Resize appliance for better fit to eliminate leakage.</p> <p>After bathing with a pouch on, towel dry barrier, pouch and skin very well to prevent trapping of moisture.</p> <p>If topical treatment is not effective, the physician may consider an administration of an oral antifungal.</p>



**Table 4. Trouble-Shooting Section**

Complication	Definition	Treatment
Non-Pouching Option	<p>An ileostomy usually has liquid or paste-like consistency with proteolytic enzymes that can breakdown the skin upon contact, so a pouch is necessary.</p> <p>A colostomy produces more normal infant stool, thus is not as irritating to the skin, so a pouch could be optional if stool can be contained in the diaper.</p> <p>Young infants and children with urinary diversions, especially a vesicostomy, are frequently managed with a diaper because it can be difficult to get an appliance to adhere well. Many urinary diversions are flush with the skin or located in a crease or on the flank which can make successful pouching difficult.</p> <p>Non-pouching option is usually for infants but may be a temporary measure for an older child with extensive skin breakdown to allow the skin to heal before pouching can be resumed.</p> <p><u>Non-Pouching Advantages:</u></p> <ul style="list-style-type: none"> <li>• Simplicity</li> <li>• More cost effective</li> <li>• Less procedural trauma</li> </ul> <p><u>Non-Pouching Disadvantages:</u></p> <ul style="list-style-type: none"> <li>• Increased possibility of excoriation</li> <li>• Decreased observation of skin</li> <li>• No accurate monitoring of stool</li> </ul> <p><u>Pouching Advantages:</u></p> <ul style="list-style-type: none"> <li>• Simple daily care routine</li> <li>• Accurate measurement of output</li> <li>• Less possibility of skin breakdown</li> <li>• No odor</li> <li>• Increased mobility of infant</li> </ul> <p><u>Pouching Disadvantages:</u></p> <ul style="list-style-type: none"> <li>• Potential for contact or irritant dermatitis</li> <li>• Frequent pouch changes</li> <li>• Cost of ostomy supplies</li> <li>• Accessibility of ostomy supplies</li> </ul>	<p><u>Fecal Stomas</u> – must protect the peristomal skin from the effluent. May use alcohol-free liquid skin barrier as the first layer and then a protective skin preparation (e.g., petrolatum or zinc- based moisture barriers). Excoriated skin may be dusted with skin barrier (ostomy) powder first prior to liquid skin barrier. Do not apply skin barrier (ostomy) paste as a barrier. Fluffed gauze, diaper or absorbent dressing may be placed around the stoma to absorb effluent. Return to a pouching system as soon as possible.</p> <p><u>Urinary Stomas</u> – good hygiene, may use a larger diaper or an absorbent pad to cover the stoma. Change diaper frequently. Use protective skin preparations.</p> <p>Gently cleanse skin with mild cleansing agents, rinsing and drying well before new diaper is applied. Routine complete removal of protective skin preparations is not necessary and may irritate skin. Removal of the protective skin preparations may be done by soaking with warm water, using cotton balls or with a soft cloth and mineral oil.</p>

**Table 4. Trouble-Shooting Section**



Complication	Definition	Treatment
<p>Prolapse</p>  <p>Distal end prolapse</p>  <p>Prolapse with color change</p>  <p>Radial Slits</p>	<p>This appears as a protrusion of the stoma through the abdominal wall in a telescoping fashion. It occurs more frequently in loop stomas located in the distal colon and is aggravated by increased abdominal pressure, such as crying. In an infant, prolapse may be intermittent when the baby cries but when calm the stoma may reduce. It is commonly seen in Hirschsprung's disease; the bowel decreases in size after the release of the obstruction but the opening in the fascia remains large.</p>	<p>A larger pouch may be required to accommodate the prolapsed stoma without trauma. A liquid skin barrier may be needed to protect peristomal skin under the prolapsed stoma, which remains moist and is prone to breakdown.</p> <p>Use caution when using a two-piece pouch due to the risk of strangulation of the stoma within the hard plastic flange, pinching the bowel between the two flanges when snapped together or causing a laceration.</p> <p>The pouch wafer may be modified with radial slits (see photo) to the wafer that will expand as the prolapse enlarges. Two pouch sizes may need to be ordered to accommodate the prolapse (one larger than the other).</p> <p>Only reduce the bowel as necessary, to fit into the pouch. Prolapsed stomas typically do not stay reduced when they are physically eased back into the abdomen and often prolapse again. If reducing the bowel, do so when child is calm by using cold compresses and gentle pressure working both hands, starting at distal portion and progressively making sure the portion of the bowel is eased back into the abdomen does not slide out again.</p> <p>Support over the reduced stoma with a hernia binder may be helpful during sport activities. Prolapse alone is not an indication for immediate intervention. If symptoms progress to include abdominal pain, decreased output, s/s of obstruction or prolonged change in color of the stoma not associated with crying, it will be necessary to seek immediate intervention.</p> <p>A progressively prolapsing stoma, particularly if associated with ischemia and abdominal pain, may be indicative of incarceration and usually requires immediate surgical intervention.</p>

**Table 4. Trouble-Shooting Section**

Complication	Definition	Treatment
<p>Retention Ring/ Rod in Stoma</p>  <p>Retention rod.</p>  <p>Retention ring.</p>	<p>Loop stomas, such as with Hirschsprung's disease, are often stabilized on the abdominal surface by a retention ring or rod until the abdominal wall heals. The loop stoma is usually oval in shape, temporary, and may be constructed anywhere in the intestine. The retention ring is usually a loop of red rubber catheter. The retention rod is usually a short piece of catheter that is slid under the stoma with each end visible on either side of the stoma. The retention ring/rod is removed at the discretion of the surgeon approximately one to two weeks after surgery.</p>	<p>Cut pouch opening slightly larger than stoma, may need to squeeze retention ring to elongate and fit through opening as pouch is applied.</p> <p>For the stoma with the retention rod, apply dabs of stoma paste on either side of rod to seal and level skin. Cut pouch opening to easily fit over just the stoma (usually 1/8-inch larger than stoma). Apply stoma paste around opening cut for stoma and apply the pouch. The retention rod will be under the wafer. The use of moldable strip paste may be used instead of stoma paste.</p>



**Table 4. Trouble-Shooting Section**

Complication	Definition	Treatment
<p>Retraction</p> 	<p>A retracted stoma is one that has receded below skin level due to excessive tension on the mesentery. This causes problems because effluent stagnates near the opening and forces leakage under the appliance resulting in difficulty to maintain a pouch seal. A skin-level scar may also cause obstruction problems with a retracted stoma.</p> <p>Table 4. Trouble-Shooting Section</p>	<p>No immediate intervention is necessary unless partial or complete mucocutaneous separation of the stoma from the skin layer occurs.</p>
<p>Stomal Stenosis</p> 		<p>Superficial detachment affecting only the skin level may require antibiotics. Monitor for the spread of effluent to subcutaneous tissue and cellulitis. If detachment reaches the fascial level, there is an increase risk for peritonitis and immediate surgical intervention is necessary.</p>
<p>Creating convexity</p>		<p>Once healing has occurred so there is no concern about mucocutaneous separation, a pouch with convexity can help to push the surrounding skin back so stoma will protrude. One- and two- piece pouches are available with built in convexity (mild, moderate, deep). Skin barrier (ostomy) paste may be indicated to help fill in uneven creases.</p> <p>A retracted or flush stoma in a deep skin crease may not be able to accommodate convexity. A flexible one-piece pouch may be tried. The use of a stoma belt with a convex pouch may help evert the stoma opening.</p> <p>Convexity may also be created with barrier supplements/strips or plastic inserts (See photo).</p>

**Table 4. Trouble-Shooting Section**


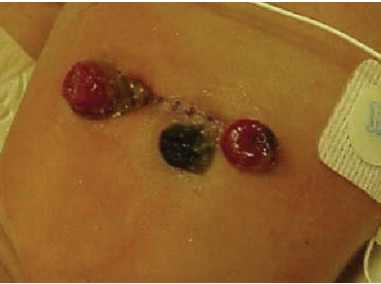
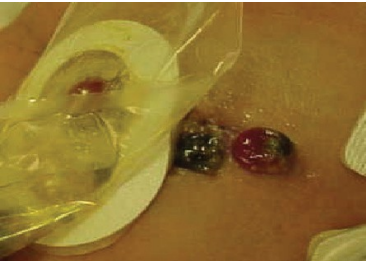
Complication	Definition	Treatment
Skin Hyperplasia (Pseudo- verrucous lesions)	This is an overgrowth of tissue that is exposed to a chronic irritant that is usually urine. A pseudo-verrucous lesion, a raised wart like lesion, is most commonly associated with urinary stomas but may develop in a patient with an ileostomy or colostomy. The lesions occur at the base of the stoma with a grey or silver hyperpigmentation that bleeds easily and is painful. This is commonly caused by an improperly sized appliance.	<p>Correct underlying problem. Evaluate pouch equipment; pouch opening is often too large.</p> <p>Choose a pouch with an extended-wear barrier to hold up to urine.</p> <p>Refit pouch to cover area, increase oral fluid to acidify urine, change diaper frequently.</p> <p>Instruct to increase oral fluid intake to dilute urine.</p> <p>[Urinary Crystal Deposits – acidification of urine with Vitamin C may be prescribed to treat alkaline urine. Use of Vitamin C in children has been shown to interfere with calcium absorption. Use only after confirming with pediatric urologist.</p> <p>Peristomal skin and stoma can be treated with one-fourth to one-half strength white vinegar soaks with each appliance change. The vinegar helps dissolve the gritty white crystal deposits (alkaline encrustation).]</p>
Stoma Bleeding	The stomal mucosa contains many small blood vessels close to the surface. Superficial bleeding can occur from minor trauma such as with cleaning, friction from the pouch, shaving abdominal hair with incorrect technique or sports- related injuries. Hemorrhage or profuse bleeding from the stoma site may be an indication of more serious conditions such as portal hypertension, trauma, recurrent disease, etc.	<p>Minor superficial bleeding should stop spontaneously.</p> <p>If bleeding doesn't stop, apply direct pressure with cold compresses or cauterization (suture or topical hemostatic agents such as silver nitrate or absorbable hemostat such as Surgicel®) may be required.</p> <p>Assess severity of bleeding and cause, take measures to control the bleeding.</p> <p>Apply flexible one-piece appliance or flexible two-piece adhesive coupling appliance with appropriate opening for stoma, gentle stomal/peristomal care, monitor bleeding.</p> <p>If bleeding occurred from trauma, discuss self-care techniques with patient.</p> <p>Monitor pouch change frequency. Use caution with patients with bleeding disorders, such as thrombocytopenia or portal hypertension.</p>




**Table 4. Trouble-Shooting Section**

<b>Complication</b>	<b>Definition</b>	<b>Treatment</b>
Stomal Hyperplasia	This is an overgrowth of tissue on the stoma most often related to trauma from activity or from the pouch itself. The lesions will often bleed with cleansing or pouch changes.	<p>Evaluate pouch fit. May need to enlarge opening to not irritate stomal lesions.</p> <p>Xeroform® gauze, a calcium alginate dressing, or topical hemostatic agent (i.e., silver nitrate or absorbable hemostat) may be used to control the bleeding of the lesions.</p>
Stomal Necrosis	This is a postoperative complication of inadequate blood supply to the stoma resulting in the death of the mucosal tissue on the surface of the stoma. The stoma will often appear dark red, purple, bluish, brown or black. It may involve only the exteriorized portion of the stoma or the entire stomal loop. Necrosis can occur five to seven days after surgery, and stoma color may change from red to purple to grey or black.	<p>Document the color changes and notify the physician.</p> <p>Apply transparent pouches postoperatively; size them to clear the stoma easily. The superficial layer may slough and debride. A foul odor is usually noted during this sloughing process.</p> <p>Partial ischemia, surgery is not indicated just monitor, use a soft pouch with gentle cleansing until the necrosis sloughs off.</p> <p>Reoperation to resect the necrotic portion may be necessary if the bowel below the fascial level becomes necrotic and a new ostomy will need to be reconstructed.</p>

**Table 4. Trouble-Shooting Section**

Complication	Definition	Treatment
<p>Stomal Stenosis</p>  <p>Stomal stenosis</p>	<p>The stomal lumen becomes narrow and rigid and typically occurs at either the fascial or cutaneous level. This is caused by several factors such as an insufficient skin incision to bring the stoma through, alkaline urine with a urinary stoma, stomal necrosis, muco- cutaneous separation, excessive scar tissue formation from repeated dilation of the stoma. Patient will have reduction or elimination of output, diarrhea, cramping pain, or s/s of obstruction.</p>	<p>Preventative measures include maintenance of a secure pouch seal to prevent peristomal skin breakdown, urine acidification measures, and prompt treatment of hyperplasia.</p> <p>Daily stoma dilation may be an effective temporizing measure and may be used at the discretion of the surgeon.</p> <p>May create a stomal stent to be placed into the stoma by using a catheter threaded on a suture and secured with the flange of a two-piece system.</p> <p>Assess for symptoms of partial obstruction.</p> <p>Short term option is stomal dilation.</p> <p>If s/s of obstruction, surgery may be necessary.</p>
<p>Umbilical Stump adjacent to the Stoma</p>  <p>Umbilical Stump</p>  <p>Pouched.</p>	<p>Infants with stomas who have an intact umbilical stump close to the pouching area may experience problems with keeping the umbilical stump dry or with loosening of the pouch wafer. If the pouch wafer overlaps onto the umbilical stump, it will stay moist and delay detachment of the stump and may moisten the edges of the pouch wafer.</p>	<p>May need to picture frame edges of pouch using a hydrocolloid dressing, transparent film dressing or waterproof tape to protect from adjacent moisture from umbilicus or cleaning products for the umbilicus. Offset the stomal opening in pouch wafer in order to avoid umbilicus. Trim edges of the wafer to avoid umbilicus.</p> <p>May also fold the pouch back onto itself so it is kept off of the umbilical stump to allow air to circulate.</p>

**Table 4. Trouble-Shooting Section**

Complication	Definition	Treatment
<p>Wound or Incision Adjacent to Stoma</p> 	<p>This situation is commonly seen in premature infants who have small pouching surfaces but may be seen in any age group.</p>	<p><u>Surgical incision:</u> The pouch wafer barrier can be placed directly over the surgical incision through which a stoma has been brought out.</p> <p><u>Wound:</u> Wound can be filled in with a skin barrier (ostomy) powder or an absorbent dressing and covered with hydrocolloid dressing to create a pouching surface. Skin barrier (ostomy) paste or barrier supplements/strips may improve the pouch seal.</p> <p>If frequent dressing changes are required for wound care, a wound management system, which allows access to the wound while containing effluent from the stoma, may be useful.</p> <p>Negative pressure wound therapy (NPWT) may be used on open abdominal wounds that are in close proximity to the stoma. The NPWT dressing is applied first, and then the stoma is pouched. The pouch may overlap onto the abdominal dressing. The pouch and dressing changes can be done every two or three days.</p>

### References for Trouble Shooting

- Brown, K. C., Ricketts, R. R. Current management of the neonatal patient with an ostomy 1994; 6(3):3-16.
- Budhiraja, S. Non-prolapsing colostomy in a massively dilated colon. Tropical Doctor 2002; 32:31-32.
- Garvin, G. Caring for children with ostomies. Nurs Clinics of North America 1994; 29(4):645-654.
- Hagelgans, N. A., Janusz, H. B. Pediatric skin care issues for the home care nurse: Part 2. Pediatric Nurs 1994; 20(1):69-75.
- McCann, E. M. Common ostomy problems. In: Milne, C. T., Corbett, L. Q., Dubuc, D. L., editors. Wound, ostomy, and continence nursing secrets. Philadelphia: Hanley & Belfus, Inc; 2003. p 319-325.
- Hampton, B. G. Peristomal and stomal complications. In: Hampton, B. G., Bryant, R. A., editors. Ostomies and continent diversions. St. Louis, MO: Mosby Year Book, Inc.; 1992. p105-123.
- Garvin, G. Skin care considerations in the neonate for the ET nurse. J Enterostom Ther 1990; 17:225-30. Black, P. Treating peristomal skin problems in the community. British J Community Nurs 2002; 7(4): 2-217.
- Hanlon, M. Pouching challenges in a patient with extensive peristomal skin loss and subsequent skin graft. JWOCN 1999; 26(1):48-52.
- Harrell-Bean, H. A., Klell, C. A. Neonatal ostomies. JOGN Nursing 1983.

## Glossary

**Anorectal malformation** – Congenital malformation encompassing anomalies of rectum and urinary and repro- duction structures.

**Bladder exstrophy** – A congenital defect with eversion of bladder and urethra through defect in abdominal wall.

**Chronic Intestinal Pseudo-Obstruction (CIP)** – Rare disorder of intestinal motility in which peristalsis becomes altered and inefficient.

**Cloacal exstrophy** – A portion of the large intestines lies outside of the body, and on either side of it are the two halves of the bladder. In males, the penis is usually flat and short, sometimes split in half. In females, the clitoris is split.

**Colostomy** – A fecal diversion that uses a segment of the colon that is surgically brought through the abdominal wall.

**Conduit** – A urinary stoma formed when a short length of intestine (ileum or large bowel) is resected from the bowel and one end is used to form a stoma on the abdomen. The ureters are implanted into the resected portion of the bowel, and this bowel segment is sewed closed inside the abdomen.

**Crohn's disease** – Predominately full-thickness inflammatory disease of the bowel affecting any segment of the alimentary canal, from mouth to anus.

**Distal portion** – Refers to section of bowel that is toward the rectum.

**Diversion colitis** – An inflammation of the colonic mucosa of the non-functional bowel that is associated with mucus discharge and bleeding and may culminate in stricture formation.

**Double barrel ostomy** – Formed similar to end ostomy (see End ostomy), but results in two stomas on the abdomen; the proximal stoma expels stool and the distal stoma or mucous fistula, expels mucous.

**End ostomy** – Ostomy constructed by taking a segment of the bowel and dividing it into two pieces. The proximal end is brought out of the abdomen as a single stoma, and the distal end may be sutured closed and left in place or removed.

**Epispadia** – A congenital defect where the bladder is completely formed but the urethra opening placement is abnormal (Colwell et al., 2004).

**Familial Adenomatous Polyposis (FAP)** – Rare, inherited disorder characterized by the development of multiple polyps in the colon or other organs.

**Hirschprung's disease** – Congenital absence of ganglion cells in the distal intestine. It starts at the anus and progresses upward.

**Hydronephrosis** – Abnormal enlargement of a kidney secondary to ureteral obstruction or chronic kidney dis- ease.

**Ileostomy** – A fecal diversion that uses a segment of the ileum that is surgically brought through the abdominal wall.

**Jejunostomy** – A fecal diversion that uses a segment of the jejunum that is surgically brought through the abdominal wall.

**Loop ostomy** – Ostomy constructed by bringing a loop of bowel through the abdominal wall.

**Myelomeningocele** – A congenital defect in which the neural arches fail to close and expose contents of the spinal bladder.

**Nephrostomy/pyelostomy** – Urinary stoma in which a connection to the renal pelvis, by insertion of a percutaneous tube, relieves hydronephrosis.

**Ostomy** – Surgically created opening. For our purposes, we are referring to an opening in the abdomen to divert waste, stool or urine.

**Posterior urethral valves** – Irregular folds or leaflets of tissues that cause urine flow obstruction.

**Proximal portion** – Refers to section of the bowel that is coming from the direction of the mouth.

**Prune belly syndrome** – This condition is named for the wrinkly appearance of the abdominal skin caused by absent abdominal musculature. It can also be associated with undescended testes, dilated ureters and calyces, clubbed feet and heart and lung abnormalities.

**PSARP** – Posterior sagittal anorectoplasty for the repair of high anorectal malformations.

**Stoma maturation** – Surgical process during which mucosa is everted and sutured to the abdominal skin, creating a stoma with a “bud” appearance.

**Ulcerative colitis** – Inflammatory changes of the rectal and colonic mucosa of unknown cause.

**Ureterostomy** – Urinary stoma in which ureters are separated from the urinary system and brought out to the skin.

**Urostomy** – Non-specific, general term used to describe urinary diversions.

**Vesicostomy** – An opening is made through the suprapubic abdominal wall into the bladder and the bladder mucosa is sutured to the abdominal skin to create a small stoma which may have the appearance of a small hole.

## Appendix A. Resources

The following list includes many of the items/supplies listed or discussed in this document. It is not all-inclusive as products and manufacturers are continuously adding and deleting items as needed.

### Product/Manufacturer Resources

Intestinal Ostomy Pouches: Premature Infant	
Manufacturer	Appliance
ConvaTec, Princeton, NJ	Eakin Fistula and Wound Pouch
Dansac A/C, Fredensborg, Denmark Hollister Inc., Libertyville, IL	CombiMicro Mini Infant Soft D Pouch
Incutech, Inc., Kernersville, NC	Pouchkins Preemie Ostomy Pouch Pouchkins Newborn Ostomy Pouch Pouchkins One-piece Pediatric Pouch
Marlen Manufacturing & Development Co., Bedford, OH	Preemie Pouch
Nu-Hope Laboratories, Inc., Pacoima, CA	“Ultra” Infant-Ileo Pouch  Neonatal Pouch Systems

Intestinal Ostomy Pouches: Infant/Pediatric	
Manufacturer	Appliance
Coloplast Corporation, Minneapolis, MN	One-piece Pediatric Pouch Two-piece Pediatric Pouch
Convatec, Princeton, NJ	Little Ones Active Life One Piece Little Ones Sur-Fit Natura Two-piece
Cymed Ostomy Co., Berkeley, CA	One-piece Drainable-Mini (Pediatric), w and w/o wafer CombiMicro Mini Infant Soft D
Dansac A/C, Fredensborg, Denmark	Pouchkins One-piece Pediatric Pouch Pouchkins Two-piece Pediatric Pouch
Hollister Inc., Libertyville, IL	“Ultra” Pedi-Ileostomy Pouch
Marlen Manufacturing & Development Co., Bedford, OH	Neonatal Pouch Systems Nu-Flex Mini Round-Mini Drainable Nu-Flex Mini Oval-Mini Drainable
Nu-Hope Laboratories, Inc., Pacoima, CA	Non-disposable Infant Standard One-Piece and Two-Piece Appliance, absolute flat and 3 levels of convexity
Perma-Type Company, Inc., Plainville, CT	



<b>Pediatric Urostomy Pouches</b>	
Coloplast Corporation, Minneapolis, MN	One-piece Pediatric Urostomy
ConvaTec, Princeton, NJ	Two-piece Pediatric Urostomy
Cymed Ostomy Co., Berkeley, CA Hollister Inc., Libertyville, IL	Little Ones Active Life One Piece Urostomy
	Little Ones Sur-Fit Natura Two-piece Urostomy
Marlen Manufacturing & Development Co., Bedford, OH	Mini Urostomy Pouching System, w and w/o wafer
Nu-Hope Laboratories, Inc., Pacoima, CA	Pouchkins One-piece Urostomy Pediatric Pouch
Perma-Type Company, Inc., Plainville, CT	Pouchkins Two-piece Urostomy Pediatric Pouch
	"Ultra" Pedi-Urostomy Pouch
	Nu-Flex Mini Urinary Pouch w and w/o flutter valve
	Non-disposable Infant Standard One-Piece and Two-Piece Appliance, absolute flat and 3 levels of convexity

## National Organizations

### **Wound, Ostomy and Continence Nurses Society**

WOCN National Office  
1120 Route 73, Suite 200 • Mount Laurel, NJ 08054-2212  
888-224-WOCN (9626) • [www.wocn.org](http://www.wocn.org)

### **United Ostomy Association of America (UOAA)**

P. O. Box 512 • Northfield, MN 55057-0512  
800-826-0826 • [www.ostomy.org](http://www.ostomy.org)

### **Pull-thru Network**

2312 Savoy Street • Hoover, AL 35226-1528  
205-978-2930 • [www.pullthrurnetwork.org](http://www.pullthrurnetwork.org)

### **Crohn's & Colitis Foundation of America**

386 Park Avenue South, 17th Floor • New York, NY 10016-8804  
800-932-2423 • [www.ccfa.org](http://www.ccfa.org)

### **Reach Out for Youth with Ileitis and Colitis, Inc.**

P. O. Box 857 • Bellmore, NY 11710  
631-293-3102 • [www.reachoutforyouth.org](http://www.reachoutforyouth.org)

## References

- Adams, D. A., & Selekof, J. L. (1986). Children with ostomies: Comprehensive care planning. *Pediatric Nursing*, 12(6), 429- 433.
- Arnsmeier, S. L., & Paller, A. S. (1997). Getting to the bottom of diaper dermatitis. *Contemporary Pediatrics*, 14(11), 115- 129.
- Association of Women's Health, Obstetric and Neonatal Nurses. (2001). Evidence-based clinical practice guideline: Neonatal skin care. Washington, D.C.: Association of Women's Health, Obstetric and Neonatal Nurses.
- Berg, R. W. (1987). Etiologic factors in diaper dermatitis: A model for development of improved diapers. *Pediatrician*, 14 Suppl 1(1), 27-33.
- Bergevin, C. (1997). A tip on better application of paste on pediatric appliance. *CAET Journal*, 16(4), 31. Boarini, J. H. (1989). Principles of stoma care for infants. *Journal of Enterostomal Therapy*, 16(1), 21-25. Boiko, S. (1999). Treatment of diaper dermatitis. *Dermatologic Clinics*, 17(1), 235-240.
- Boiko, S. (2000). Making rash decisions in the diaper area. *Pediatric Annals*, 29(1), 50-56.
- Borkowski, S. (1998). Pediatric stomas, tubes, and appliances. *Pediatric Clinics of North America*, 45(6), 1419-1435.
- Brook, I. (1992). Microbiology of secondarily infected diaper dermatitis. *International Journal of Dermatology*, 31(10), 700- 702.
- Brown, K. C., & Ricketts, R. R. (1994). Current management of the neonatal patient with an ostomy. *Progressions*, 6(3), 3-16.
- Bryant, R. A., & Buls, J. G. (1992). Pathophysiology and diagnostic studies of gastrointestinal tract disorders. In B. G. Hampton, & R. A. Bryant (Eds.), *Ostomies and continent diversions: Nursing management* (pp. 299-348). St. Louis, MO: Mosby.
- Campbell, R. L., Seymour, J. L., Stone, L. C., & Milligan, M. C. (1987). Clinical studies with disposable diapers containing absorbent gelling materials: Evaluation of effects on infant skin condition. *Journal of the American Academy of Dermatology*, 17(6), 978-987.
- Caty, M., & Azizkhan, R. (2000). Necrotizing enterocolitis. In W. Ashcraft (Ed.), *Pediatric surgery* (3rd ed., pp. 443-452). Philadelphia: W. B. Saunders.
- Colwell, J. C., Goldberg, M. T., & Carmel, J. E. (2004). Fecal & urinary diversions: Management principles. In *Fecal & urinary diversions: Management principles* (pp. 263-307). St. Louis, Missouri: Elsevier Mosby, Inc.
- Cuckow, P. (1998). Posterior urethral valves. In M. D. Stringer, K. T. Oldham, P. D. Mouriquand, & E. R. Howard (Eds.), (pp.487-500). London: W. B. Saunders Company Ltd.

- Darmstadt, G. L., & Dinulos, J. G. (2000). Neonatal skin care. *Pediatric Clinics of North America*, 47(4), 757-782.
- Embon, C. M. (1990). Ostomy care for the infant with necrotizing enterocolitis: Nursing considerations. *The Journal of Perinatal & Neonatal Nursing*, 4(3), 56-63.
- Erwin-Toth, P., & Doughty, D. B. (1992). Principles and procedures of stoma management. In B. G. Hampton, & R. A. Bryant (Eds.), *Ostomies and continent diversions: Nursing management* (pp. 29-104). St. Louis, MO: Mosby.
- Evans, N. J., & Rutter, N. (1986). Development of the epidermis in the newborn. *Biology of the Neonate*, 49(2), 74-80.
- Falkenstein, K., Brass, C., & Palmer, J. (2000). Pediatric abdominal organ transplants. In B. V. Wise, C. McKenna, G. Garvin, & B. J. Harmon (Eds.), *Nursing care of the general pediatric surgical patient* (pp. 408-430). Gaithersburg, MD: Aspen Publications.
- Garvin, G. (1990). Discharge preparation of the pediatric patient with an ostomy. *Progressions*, 2(2), 12-19.
- Garvin, G. (2000). Caring for children with ostomies and wounds. In B. V. Wise, C. McKenna, G. Garvin, & B. J. Harmon (Eds.), *Nursing care of the general pediatric surgical patient* (pp. 261-272). Gaithersburg, MD: Aspen Publications.
- Garvin, G. (1990). Skin care considerations in the neonate for the ET nurse. *Journal of Enterostomal Therapy*, 17(6), 225-230.
- Garvin, G. (1994). Caring for children with ostomies. *The Nursing Clinics of North America*, 29(4), 645-654.
- Gauderer, M. W. (1998). Stomas of the small and large intestine. In J. A. O'Neill, M. I. Rowe, J. L. Grosfeld, E. W. Fonkalsrud, & A. G. Coran (Eds.), *Pediatric surgery*, volume 2 (5th ed., pp. 1349-1359). St. Louis, MO: Mosby.
- Gearhart, J. P. (1999). Bladder and cloacal exstrophy. In E. T. Gonzalez, & S. B. Bauer (Eds.), *Pediatric urology practice* (pp. 339-363). Baltimore, MD: Lippincott Williams & Wilkins.
- Gonzalez, J., & Hogg, R. J. (1981). Metabolic alkalosis secondary to baking soda treatment of a diaper rash. *Pediatrics*, 67(6), 820-822.
- Guardino, K. O. (2000). Anorectal malformations in children. In B. V. Wise, C. McKenna, G. Garvin, & B. J. Harmon (Eds.), *Nursing care of the general pediatric surgical patient* (pp. 247-260). Gaithersburg, MD: Aspen Publications.
- Hagelgans, N. A. (1993). Pediatric skin care issues for the home care nurse. *Pediatric Nursing*, 19(5), 499-507.
- Hagelgans, N. A., & Janusz, H. B. (1994). Pediatric skin care issues for the home care nurse: Part 2. *Pediatric Nursing*, 20(1), 69-74, 76.

- Hansen, R. C., Krafchik, B. R., Lane, A. T., Odio, M. R., & Schachner, L. A. (1998). Dealing with diaper dermatitis. *Contemporary Pediatrics*, (Supplement), 5-12.
- Harpin, V., & Rutter, N. (1982). Percutaneous alcohol absorption and skin necrosis in a preterm infant. *Archives of Diseases in Childhood*, 57, 477-479.
- Harpin, V. A., & Rutter, N. (1983). Barrier properties of the newborn infant's skin. *The Journal of Pediatrics*, 102(3), 419-425.
- Harrell-Bean, H. A., & Klell, C. A. (1983). Neonatal ostomies. *JOGN Nursing; Journal of Obstetric, Gynecologic, and Neonatal Nursing*, 12(3 Suppl), 69s-73s.
- Hoath, S. B., & Narendran, V. (2000). Adhesives and emollients in the preterm infant. *Seminars in Neonatology* : SN, 5(4), 289-296. doi:10.1053/siny.2000.0015
- Hyman, P. E. (1999). Chronic intestinal pseudo-obstruction. In R. Wyllie, & J. S. Hyams (Eds.), *Pediatric gastrointestinal disease: Pathophysiology, diagnosis, management* (2nd ed., pp. 433-442). Philadelphia, PA: W. B. Saunders Company.
- Irving, V. (2001). Reducing the risk of epidermal stripping in the neonatal population: An evaluation of an alcohol-free barrier film. *Journal of Neonatal Nursing*, 7(1), 5-8.
- Ittmann, P. I., & Bozynski, M. E. (1993). Toxic epidermal necrolysis in a newborn infant after exposure to adhesive remover. *Journal of Perinatology*, 13(6), 476-477.
- Jarosz, E. E., Haga, L. J., & Ramasethu, J. (2002). Neonatal ostomy and gastrostomy care. In M. G. MacDonald, & J. Ramasethu (Eds.), *Procedures in neonatology* (pp. 323-331). Philadelphia, PA: Lippincott Williams & Wilkins.
- Joyner, B. D., & Khoury, A. E. (1999). The role of urinary diversion in childhood: Temporary, continent and otherwise. In E. T. Gonzalez, & S. B. Bauer (Eds.), *Pediatric urology practice* (pp. 687-704). Baltimore, MD: Lippincott Williams & Wilkins.
- Kalia, Y. N., Nonato, L. B., Lund, C. H., & Guy, R. H. (1998). Development of skin barrier function in premature infants. *The Journal of Investigative Dermatology*, 111(2), 320-326. doi:10.1046/j.1523-1747.1998.00289.x
- Lund, C. (1984: December). Skin care in the intensive care nursery: Part III stoma care. *Neonatal Network*, 28-34.
- Lund, C. (1999). Prevention and management of infant skin breakdown. *The Nursing Clinics of North America*, 34(4), 907-20, vii.
- Lund, C. H., Nonato, L. B., Kuller, J. M., Franck, L. S., Cullander, C., & Durand, D. J. (1997). Disruption of barrier function in neonatal skin associated with adhesive removal. *The Journal of Pediatrics*, 131(3), 367-372.

- Malloy-McDonald, M. B. (1995). Skin care for high-risk neonates. *Journal of Wound, Ostomy, and Continence Nursing: Official Publication of the Wound, Ostomy and Continence Nurses Society/WOCN*, 22(4), 177-182.
- Millar, A. J., Rode, H., & Cywes, S. (2000). Intestinal atresia and stenosis. In W. Ashcraft (Ed.), *Pediatric surgery* (3rd ed., pp. 406-424). Philadelphia, PA: W. B. Saunders Company.
- Motomatsu, K., Adachi, H., & Uno, T. (1979). Two infant deaths after inhaling baby powder. *Chest*, 75(4), 448-450.
- National Advisory Service for Parents of Children with a Stoma (NASPCS). (2000). *Our special children: A practical guide to stoma care in babies and young children*. High Wycombe, Bucks, United Kingdom: CliniMed Limited.
- Pairaudeau, P. W., Wilson, R. G., Hall, M. A., & Milne, M. (1991). Inhalation of baby powder: An unappreciated hazard. *BMJ (Clinical Research Ed.)*, 302(6786), 1200-1201.
- Parry, A. (1998: January). Stoma care in neonates: Improving practice. *Journal of Neonatal Nursing*, 4(1), 8-11.
- Pediatric Subcommittee of the Wound, Ostomy and Continence Nurses Society. (2010). Trouble-shooting section on pediatric best practice guideline. Retrieved September 1, 2010, from [http://www.wocncenter.com/uploaded\\_documents/pdf/Ped.Trouble.Shooting.9.10.08.pdf](http://www.wocncenter.com/uploaded_documents/pdf/Ped.Trouble.Shooting.9.10.08.pdf)
- Pieper, P. (2000). Pediatric trauma. In B. V. Wise, C. McKenna, G. Garvin, & B. J. Harmon (Eds.), *Nursing care of the general pediatric surgical patient* (pp. 459-479). Gaithersburg, MD: Aspen Publications.
- Plaas, K. (1997). *Neonatal skin care guidelines for practice*. Petaluma, CA: National Association of Neonatal Nurses.
- Rescorla, F. J. (1998). Meconium ileus. In J. A. O'Neill, M. I. Rowe, J. L. Grosfeld, E. W. Fonkalsrud, & A. G. Coran (Eds.), *Pediatric surgery* (5th ed., pp. 1159-1172). St. Louis, MO: Mosby.
- Roberts, P. M. (1990). NEC: Etiology, treatment, prevention, and nursing care. *Critical Care Nurse*, 10(4), 38-9, 47-54.
- Rogers, V. E. (2003). Managing preemie stomas: More than just the pouch. *Journal of Wound, Ostomy, and Continence Nursing: Official Publication of the Wound, Ostomy and Continence Nurses Society/WOCN*, 30(2), 100-110. doi:10.1067/mjw.2003.27
- Rolstad, B. S., & Boarini, J. (1996). Principles and techniques in the use of convexity. *Ostomy/wound Management*, 42(1), 24-6, 28-32; quiz 33-4.
- Rutter, N. (1987). Drug absorption through the skin: A mixed blessing. *Archives of Disease in Childhood*, 62(3), 220-221.
- Schick, J. B., & Milstein, J. M. (1981). Burn hazard of isopropyl alcohol in the neonate. *Pediatrics*, 68(4), 587-588.
- Shapiro, T., & Diana-Zerpa, J. A. (2000). Malrotation and volvulus. In B. V. Wise, C. McKenna, G. Garvin, & B. J. Harmon (Eds.), *Nursing care of the general pediatric surgical patient* (pp. 305-315). Gaithersburg, MD: Aspen Publications, Inc.

- Siegel, E., & Wason, S. (1986a). Boric acid toxicity. *Pediatric Clinics of North America*, 33(2), 363-367. Siegel, E., & Wason, S. (1986b). Camphor toxicity. *Pediatric Clinics of North America*, 33(2), 375-379.
- Touloukian, R. J., & Smith, E. I. (1998). Disorders of rotation and fixation, vol. 2. In J. A. O'Neill, M. I. Rowe, J. L. Grosfeld, E. W. Fonkalsrud, & A. G. Coran (Eds.), *Pediatric surgery* (5th ed., pp. 1199-1214). St. Louis, MO: Mosby.
- Vivier, P. M., Lewander, W. J., Martin, H. F., & Linakis, J. G. (1994). Isopropyl alcohol intoxication in a neonate through chronic dermal exposure: A complication of a culturally-based umbilical care practice. *Pediatric Emergency Care*, 10(2), 91-93.
- Webster, R., & Maibach, H. (1982). Comparative percutaneous absorption. In H. Maibach, & E. Boisits (Eds.), *Neonatal skin structure and function* (pp. 137-147). New York, NY: Marcel Dekker, Inc.
- Wells, J. A., & Doughty, D. B. (1994). Pouching principles and products. *Ostomy/wound Management*, 40(6), 50-8, 60-3. Wilson, R. E. (1994). Ostomy care for infants with necrotizing enterocolitis. *Journal of Wound, Ostomy, and Continence Nursing: Official Publication of the Wound, Ostomy and Continence Nurses Society/WOCN*, 21(5), 190-194.
- Wong, D. L., & Hockenberry, M. J. (2003). In Kline N. E. (Ed.), *Wong's nursing care of infants and children*. St. Louis, Missouri: Elsevier Science Mosby, Inc.
- Young, M. J. (1992). Convexity in the management of problem stomas. *Ostomy/wound Management*, 38(4), 53-4, 56, 59-60. Youth Rally Committee, I. (2010). The youth rally. Retrieved September 13, 2010, from <http://www.rally4youth.org/rally.php>

## **Acknowledgment About Content Validation**

*This document was reviewed in the consensus-building process of the Wound, Ostomy and Continence Nurses Society known as Content Validation, which is managed by the Center for Clinical Investigation.*